

- Sognnaes RF, Rawson RD, Gratt BM, and Hyugen NBT (1982) Computer comparison of bite mark patterns in identical twins. *J. Amer. Dent. Assn.* 105:449-451.
- Sperber N (1990) Lingual markings of anterior teeth as seen in human bite marks. *J. Forensic Sci.* 35(4): 838-844.
- Vale GL, Sognnaes RF, Felando GN, and Noguchi TT (1976) Unusual 3 dimensional bite mark evidence in a homicide case. *J. Forensic Sci.* 21(3):642-652.
- Vale GL, and Noguchi TT (1984) Anatomical distribution of human bite marks in a series of 67 cases. *J. Forensic Sci.* 28(1):61-69.
- Weigler S (1992) Bite mark evidence: forensic odontology and the law. *Health Matrix* 2(2):303-323.
- West MH, Barsley RE, Frair J, and Seal MD (1990) The use of human skin in the fabrication of a bite mark template: two case reports. *J. Forensic Sci.* 35(6):1477-1485.
- Whittaker DK, and MacDonald DG (1989) *A Colour Atlas of Forensic Dentistry.* London: Wolfe Medical Publications, LTD.

## AN UNUSUAL TALON CUSP

TRIONA MC NAMARA

*Regional Orthodontic Department, St. James's Hospital, Dublin 8, Ireland*

A 13 year-old male Caucasian presented for routine orthodontic treatment. He had a Class II division 1 malocclusion with significant crowding in both mandibular and maxillary labial anterior segments of the dentition. He had no significant medical history. Marked tubercles of Carabelli were noted on the maxillary first permanent molars. The mandibular right second molar was infra-occlusal and a facial talon cusp was noted on the permanent left mandibular central incisor (Fig. 1).

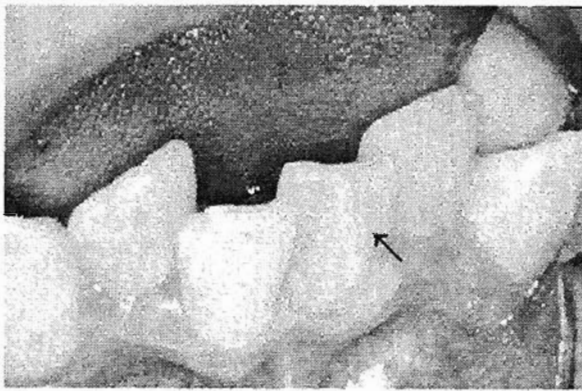


Fig. 1. 'Facial' talon cusp on a permanent mandibular left central incisor (arrow).

As the facial talon cusp of the mandibular incisor would prevent a proper reduction in overjet and ultimately interfere with the occlusion, the orthodontic treatment plan decided upon was extraction of this tooth, in addition to extraction of three of the first premolars. Uneventful fixed orthodontic appliance therapy is now underway.

The facial location of this talon cusp is unusual. The affected incisor tooth is currently being investigated to assess the extent of its pulp chamber.

The aetiology of talon cusps is unknown. However, the feature is thought to be a combination of genetic and environmental factors (Davies and Brook, 1992).

In the cases that I have found in the literature, talon cusps occurred most commonly on permanent incisors, 90% in the maxilla, with the maxillary lateral incisor the most commonly affected (Rismah, 1991). They have been reported primarily in the secondary dentition, though recent cases involving the primary maxillary incisors have been reported (Chen, 1986; Meon, 1990a,b; Rusmah, 1991). Males were more commonly affected than females, with racial variation reflected by a predominance of the feature in the Chinese population (Davies and Brook, 1992). The facial talon cusps usually occurred in single cases (Pledger, 1989; Meon, 1990a; Acs, 1992) or a few individuals (Meon, 1990b; Harris and Owsley, 1991). Talon cusps have been reported as an isolated finding (Chen, 1986) or in association with other dental anomalies such as shovel-shaped incisors, peg-shaped lateral incisors, unerupted canines, three-rooted mandibular first molars, impacted mesiodens, and odontomes (Davies and Brook, 1986; Acs, 1992). Syndromes associated with talon cusps include Mohr syndrome, *incontinentia pigmenti achromians*, and Rubenstein-Taybi syndrome (Tsutsumi, 1991; Acs, 1992).

The example of the talon cusp shown in Fig. 1 differs from most of the examples in the literature. It occurs on the facial aspect of a mandibular permanent central incisor of a Caucasian, who lacks the anomalies and syndromes associated with published cases. Therefore, I am seeking comments from readers on the facial talon cusp shown in Fig. 1. Personal findings, bibliographic references on other cases of facial talon cusps, and information about the aetiology of this anomaly also would be greatly appreciated.

### LITERATURE CITED

- Acs G (1992) Shovel incisors, three-rooted molars, talon cusp and supernumery on one patient. *Paediatr. Dent.* 13:236-237.
- Chen RJ (1986) Talon cusp in primary dentition. *Oral. Surg. Oral. Med. Oral. Path.* 62:67-72
- Davies PJ, and Brook AH (1986) The presentation of the talon cusp: diagnosis, clinical features, associates, and possible aetiology. *Brit. Dent. J.* 160:84-88.
- Harris E, and Owsley DW (1991) The talon cusp: A review with three cases from North America. *J. Tennessee Dent. Assoc.* 71:20-22.
- Meon R (1990a) Talon cusp in primary dentition-case report. *Sing. Dent. J.* 15:32-40.
- Meon R (1990b) Talon cusp in two siblings. *N. Z. Dent. J.* 86:42-44.
- Pledger DM (1989) Talon cusp: Report of two cases. *Brit. Dent. J.* 167:171-173.
- Rusmah M (1991) Talon cusp in Malaysia. *Aust. Dent. J.* 36:11-14.
- Tsutsumi T (1991) Labial talon cusp in a child with *Incontinentia pigmenti achromans*: case report. *Pediatr. Dent.* 13:236-237.