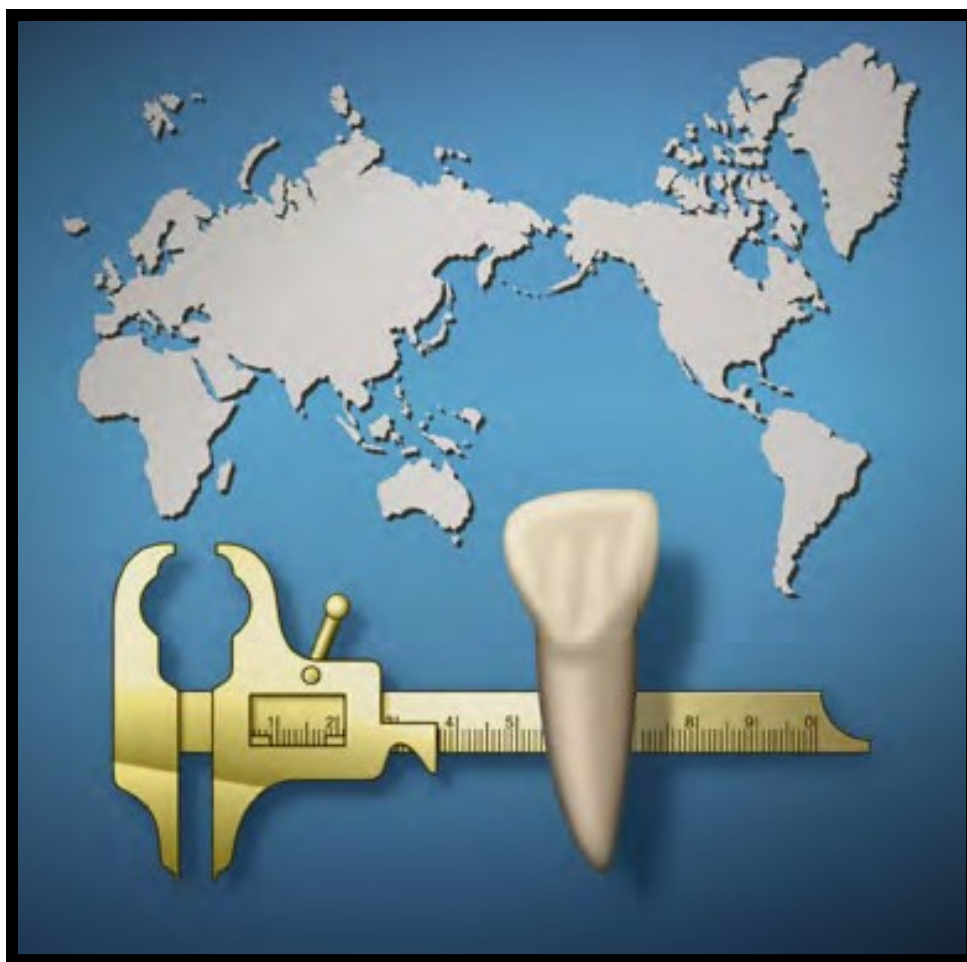

# Dental Anthropology

---

*A Publication of the Dental Anthropology Association*



# Dental Anthropology

Volume 30, Issue 01, 2017

*Dental Anthropology* is the Official Publication of the Dental Anthropology Association.

---

Editors: Marin A. Pilloud and G. Richard Scott

*Editor Emeritus: Christopher W. Schmidt*

## Editorial Board

Debbie Guatelli-Steinberg (2016-2019)	Yuji Mizoguchi (2016-2019)
Simon Hillson (2016-2019)	Grant Townsend (2016-2019)
Leslea Hlusko (2016-2019)	Chris Stojanowski (2016-2019)
Cathy M. Willermet (2016-2019)	

## Officers of the Dental Anthropology Association

Heather J.H. Edgar (University of New Mexico) President (2016-2019)  
 Daniel Antoine (British Museum) President-Elect (2016-2019)  
 Loren R. Lease (Youngstown State University) Secretary-Treasurer (2015-2018)  
 Scott Burnett (Eckerd College) Past President (2012-2016)

## Contact for Manuscripts

Dr. Marin A. Pilloud  
 Dr. G. Richard Scott  
 Department of Anthropology  
 University of Nevada, Reno  
*E-mail addresses:* mpilloud@unr.edu, grscott@unr.edu

## Address for Book Reviews

Dr. Greg C. Nelson  
 Department of Anthropology, University of Oregon  
 Condon Hall, Eugene, Oregon 97403 U.S.A.  
*E-mail address:* gcnelson@oregon.uoregon.edu

## Published at

*University of Nevada, Reno  
 Reno, Nevada 89509*

The University of Nevada, Reno is an EEO/AA/Title IX/Section 504/ADA employer

## Editorial Assistant

Rebecca L. George

## Expression of Nonmetric Dental Traits in Western European Neanderthals

Frank L'Engle Williams<sup>1,\*</sup>, Rebecca L. George<sup>2</sup>, Marie-Antoinette de Lumley<sup>3,4</sup>, Gaël Becam<sup>3,\*</sup>

<sup>1</sup>Department of Anthropology, Georgia State University, Atlanta, GA 30303

<sup>2</sup>Department of Anthropology, University of Nevada, Reno, NV 89557

<sup>3</sup>UMR 7194 CNRS, HNHP, MNHN/UPVD/CERP de Tautavel, France

<sup>4</sup>Institut de Paléontologie Humaine, Paris, France

**Keywords:** Engis 2, Hortus, Malarnaud, Montmaurin, Pech de l'Azé 1, Roc de Marsal, Scladina 1-4A

**ABSTRACT** Neanderthals of Western Europe lived across distinct ecogeographic zones from Marine Isotope Stage 7 to 3. Differences in dental morphology from seven Western European sites are compared in terms of ecogeography and chronology.

Neanderthals ( $n = 12$ ) along a north-south gradient were examined. These included the Meuse River Basin of Belgium (Engis 2 and Scladina 1-4A), Southwest France (Pech de l'Azé 1 and Roc de Marsal), the Pyrenees (Malarnaud and Montmaurin), and the Mediterranean (Hortus). Montmaurin is the oldest, followed by Scladina 1-4A and Malarnaud, whereas the others are younger.

Dental casts were prepared from Neanderthal permanent and deciduous dentition. These were described and scored, according to the ASUDAS. Comparisons of dental traits with respect to ecogeographic regions and chronological categories were constructed.

Unusual dental features observed include the anterior fovea, entoconulid, metaconulid, and Carabelli's cusp. Dental traits that distinguish ecogeographic regions are the expression of the M<sup>1</sup> hypocone and metaconule, whereas the hypoconulid and Carabelli's cusp separate chronological categories. Differences are present for the entoconulid and metaconulid in both comparisons.

Neither chronology nor ecogeography fully explains the results. Similarities in dental traits exist between Roc de Marsal, Pech de l'Azé 1 and Engis 2, and secondarily within the Hortus assemblage.

Neanderthals are known for their taurodont molar roots, shovel-shaped incisors as well as the expression of dental morphological features that are relatively uncommon in modern humans (Patte, 1959; Zubov, 1992; Bailey, 2000, 2002, 2004, 2006; Hublin et al., 2012). However, differences may also exist between Neanderthal sites, irrespective of their relationship to modern humans. Small family groups and a relatively limited degree of genetic variation may have characterized Neanderthals (Lalueza-Fox et al., 2011; Kelso and Prüfer, 2014). Using observations of dental morphology from a relatively large sample of Neanderthals ( $n = 12$ ) from Western Europe, we examine whether ecogeography or chronology (or neither) more adequately accounts for the variation observed. Six individuals from a single site (Hortus) allow for a comparison of within and between fossil assemblages to investigate the expression of nonmetric dental traits. We also note which features are commonly expressed or are unusual in this sample of Neanderthals.

**NEANDERTHALS OF WESTERN EUROPE**  
Several regions of Western Europe appear to have

been core areas of Neanderthal habitation, even when colder conditions prevailed (Hublin and Roebroeks, 2009). Neanderthal tools, faunal remains, and osteological remnants in these regions are situated primarily between Marine Isotope Stages (MIS) 5 to 3 (Soressi et al., 2007), and are evidenced as far north as Belgium to the terminus of MIS 3 (Würm II) at about 36 kya as demonstrated by the remains from Spy cave (Semal et al., 2005, 2009; Toussaint et al., 2011; Pirson et al., 2014). The earliest Neanderthal discovered in 1829-1830, Engis 2, is probably also from MIS 3 based on associated Mousterian artifacts and fauna (Twisselmann, 1971), although it could be younger, between  $26,830 \pm 430$  and  $30,460 \pm 210$  years BP (Toussaint et al., 2011). Scladina 1-4A, also located along the Meuse River Basin of Belgium, has been dated to MIS 5 or earlier (Pirson et al., 2014), attesting to the probable recolonization of the Meuse

\*Correspondence to:

Dr. Frank L'Engle Williams, Department of Anthropology, Georgia State University  
e-mail: frankwilliams@gsu.edu

Dr. Gaël Becam, UMR 7194 CNRS, HNHP, MNHN/UPVD/CERP de Tautavel, France

River Basin of Belgium after the climate deterioration of MIS 4 (Hublin and Roebroeks, 2009; Toussaint et al., 2011; Di Modica et al., 2016). Scladina 1-4A is probably between 80-87 kya based on chronostratigraphic analyses using the Greenland Record as context, although it could be as old as 127 kya (Pirson et al., 2014; Toussaint et al., 2014).

Additional Neanderthal sites in Western Europe include those from the Perigord such as Roc de Marsal, which has been dated to 60-70 kya and is close to the terminus of MIS 4 (Guérin et al., 2012), and Pech de l'Azé 1 and has been dated to 51-41 kya (Soressi et al., 2007). Further south along the slopes of the northern Pyrenees in the Ariègeois region is the site of Malarnaud, which is suggested to be from the Riss-Würm interval (MIS 5). Also from the northern Pyrenees region is Montmaurin cave which has been dated to MIS 7 (Crégut-Bonnoure et al., 2010).

The Mediterranean region may have been at least partially isolated from the Pyrenees and other areas by glacier formations in the Massif Central and in particular, the Languedoc Mountains. Between the Mediterranean coast and the piedmont region south of this glaciation is the cave of Hortus yielding between 20 and 36 Neanderthal children and adults, and dated to MIS 3 (Würm II) (Lumley, 1973, 1976). Six of the Hortus remains are examined here, including Hortus II, Hortus IV, Hortus V, Hortus VI, Hortus VIII, and Hortus XI.

Dental traits in these disparate ecogeographic zones may vary as a function of distance. Alternatively, individuals may differ with respect to time period, whereby older sites (Montmaurin, Scladina 1-4A and Malarnaud) may be distinct from the younger sites of Engis 2, Hortus, Pech de l'Azé 1 and Roc de Marsal. The explanatory pow-

er of these models is explored here with respect to the dental morphology of Western European Neanderthals.

## MATERIALS AND METHODS

A total of 12 Neanderthals from seven sites are sampled in this study. Two individuals are represented solely by deciduous molars, two preserve both deciduous and permanent teeth and seven include only the permanent molars. Table 1 lists the teeth examined by site and individual.

A macroscopic investigation of the original fossil dentition was conducted by the first author (FLW) at the Musée de l'Homme, the Centre Européen de Recherches Préhistoriques de Tautavel, the Musée national de Préhistoire, Les Eyzies-de-Tayac, the Université de Liège, and the Scladina Cave Archaeological Centre. The fossil teeth and Scladina resin casts were molded using polyvinylsiloxane (Coltène-Whaledent). Dental casts were created from the dental molds using centrifuged epoxy resin and hardener (Buehler) at the Bioarchaeology Lab of Georgia State University, and were examined by one observer (RLG) using the Arizona State University Dental Anthropology System (ASUDAS; Turner et al., 1991) and a nonmetric data scoring sheet developed by R.L. George. The dental scoring system of the ASUDAS is a replicable method in which the teeth are scored at different intervals to account for the expression of a feature. Deciduous anterior teeth were scored according to the Hanihara (1961) standards for deciduous dentition. The macroscopic observations of the original Neanderthal fossil dentition were included where necessary. However, only traits visible on the dental casts were scored and recorded using the ASUDAS.

Table 1. Neanderthal dentition used in morphology descriptions.

Fossil	Teeth examined	Ecogeography	Chronology
Engis 2	di <sup>1</sup> , dc, dm <sup>1</sup> , dm <sup>2</sup> , dm <sub>1</sub> , dm <sub>2</sub> , M <sub>1</sub>	Meuse River Basin (Belgium)	Younger
Hortus II	M <sub>1</sub>	Mediterranean (France)	Younger
Hortus IV	M <sub>1</sub> , M <sub>2</sub>	Mediterranean (France)	Younger
Hortus V	M <sub>1</sub> , M <sub>2</sub> , M <sub>3</sub>	Mediterranean (France)	Younger
Hortus VI	M <sub>3</sub>	Mediterranean (France)	Younger
Hortus VIII	M <sup>1</sup>	Mediterranean (France)	Younger
Hortus XI	M <sup>3</sup>	Mediterranean (France)	Younger
Malarnaud	M <sub>1</sub>	Pyrenees (France)	Older
Montmaurin	M <sub>1</sub> , M <sub>2</sub> , M <sub>3</sub>	Pyrenees (France)	Older
Pech de l'Azé	dm <sup>1</sup> , dm <sup>2</sup> , dm <sub>1</sub> , dm <sub>2</sub>	Southwest France	Younger
Roc de Marsal	dm <sup>1</sup> , dm <sup>2</sup> , dm <sub>1</sub> , dm <sub>2</sub>	Southwest France	Younger
Scladina 4A	dm <sup>1</sup> , dm <sup>2</sup> , M <sup>2</sup> , M <sub>1</sub> , M <sub>2</sub>	Meuse River Basin (Belgium)	Older

## RESULTS

### Engis 2

Engis 2 preserves a relatively complete immature calvarium, isolated maxilla and several teeth, and has been aged to between four and five years (Tillier, 1983; Minugh-Purvis, 1988; Toussaint et al., 2011; Williams, 2013; Williams and Cofran, 2016). The dental remains of Engis 2 examined here include the left maxillary deciduous incisors ( $di^1$  and  $di^2$ ), which are shoveled (Hanihara grade 3), and a right maxillary deciduous canine characterized by a weakly developed *tuberculum dentale* (Hanihara grade 5). The right maxillary deciduous molars ( $dm^1$  and  $dm^2$ ) are described as well as the right mandibular deciduous first molar ( $dm_1$ ) and right permanent first molar ( $M_1$ ).

The right maxillary deciduous first molar ( $dm^1$ ) exhibits small wear facets on the cusp tips, although much of the original morphology is preserved. There are a total of five cusps and the metacone can be described as only weakly developed (ASUDAS grade 3). Similarly, the hypocone is also small (ASUDAS grade 3) on  $dm^1$ .

The right maxillary deciduous molar ( $dm^2$ ) has a lack of substantial attrition. On  $dm^2$  there are four cusps, and the metacone and hypocone are visibly larger than on  $dm^1$  (ASUDAS grade 4). A small, but noticeable Carabelli's trait can be observed on the second deciduous molar ( $dm^2$ ). However, it is not an independent cusp and its distal border does not contact the lingual groove between the protocone and the hypocone (ASUDAS grade 5).

The right mandibular deciduous second molar ( $dm_2$ ) exhibits a well-developed anterior fovea which is bordered by a pronounced mesial margin (ASUDAS grade 4). The deciduous second molar ( $dm_2$ ) has five cusps inclusive of a prominent hypoconulid (ASUDAS grade 5). Furthermore, a rather large metaconulid can also be observed within the lingual groove between the metaconid and entoconid (ASUDAS grade 4) on  $dm_2$ . Two large roots are present.

The lower right first permanent molar ( $M_1$ ) was probably unerupted or in the process of eruption given the absence of substantial root development (1-2 mm in length) and the virtual lack of attrition with the possible exception of a tiny wear facet on the metaconid. The right permanent first molar ( $M_1$ ) of Engis 2 has six cusps with a weakly developed hypoconulid (ASUDAS grade 1). Lingual to the hypoconulid, a small entoconulid, or *sextum tuberculum*, is represented as a second lingual groove (ASUDAS grade 1). Furthermore, a small, but noticeable metaconulid exists within the lingual groove between the metaconid and the entoconid (ASUDAS grade 2). The groove pattern on the permanent first molar ( $M_1$ ) can be described as conforming to the "Y" pattern. A weakly developed protostylid can be observed as a small pit on the buccal surface of the protoconid (ASUDAS grade 1).

### Hortus II

Hortus II, shown in Figure 1, is represented by right and left mandibular permanent first molars and has been aged

to 7-8 years (Lumley, 1973). Hortus II is the accompanying lower jaw of the maxilla identified as Hortus III (Lumley, 1973; Minugh-Purvis, 1988). There is only minimal to moderate wear on the permanent first molars ( $M_1$ ). The left first molar ( $M_1$ ) of Hortus II (1262) preserves an anterior fovea (ASUDAS grade 3) (Lumley, 1973). The protoconid is large, pointed and separated from the hypoconid by a large buccal groove. A large, but short distobuccal groove separates the hypoconid and hypoconulid (Lumley 1973). Similarly, the lingual cusps are separated by a large lingual groove. The groove pattern of the first molar ( $M_1$ ) can be characterized as exhibiting a "Y" form. The medial ridge of the metaconid is deflected distally, although it does not approach the entoconid in size (ASUDAS grade 2). A small, well-developed metaconulid is evident (ASUDAS grade 2) (see

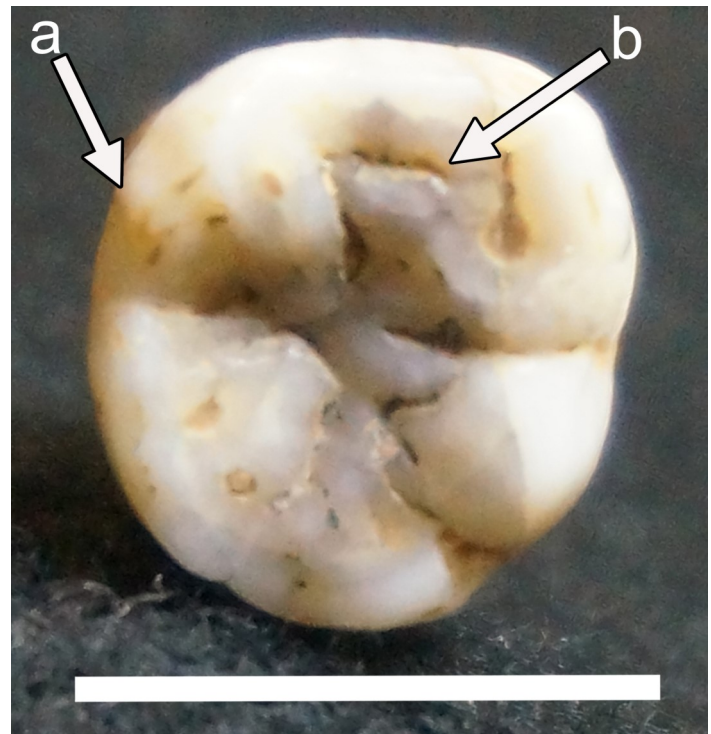


Figure 1. On the right mandibular permanent first molar ( $M_1$ ) of Hortus II, a number of dental features can be observed, such as a metaconulid (a) and an anterior fovea (b).

Fig. 1).

### Hortus IV

Hortus IV consists of a mandibular corpus and the inferior ascending ramus of a young adult aged 18-25 years (Lumley, 1973). Hortus IV preserves the left permanent first and second molars ( $M_1$  and  $M_2$ ) and the right permanent second incisor ( $I_2$ ), canine (C) and first and second molars ( $M_1$  and  $M_2$ ) *in situ*. The corpus is badly damaged, but the teeth are well preserved and only minimally worn. Heavier wear facets exist along the buccal occlusal surface of both molar rows in contrast to the lingual surfaces

(Lumley, 1973).

An anterior fovea exists on all the molars (Fig. 2; Lumley, 1973). On the right permanent first molar, the anterior fovea is represented as a large and elongated groove distal to a pronounced mesial ridge (ASUDAS grade 4) (see Fig. 2). The same could be said for the left permanent second molar ( $M_2$ ). However, the right permanent second molar ( $M_2$ ) exhibits a slightly less elongated anterior fovea than its anti-mere (ASUDAS grade 3). The groove pattern of the right permanent second molar ( $M_2$ ) evidences an "X" classification. On the second molars ( $M_2$ ), a total of six cusps can be observed and a mid-trigonid crest connects the distal borders of the protoconid and metaconid (ASUDAS grade 1). The buccal surface of the protoconid of the right second molar ( $M_2$ ) exhibits a small protostylid (ASUDAS grade 1). A prominent hypoconulid can be found on the molars (ASUDAS grade 4), although on the right second molar ( $M_2$ ) it is smaller (ASUDAS grade 3). An entoconulid can be observed lingual to the hypoconulid on the second molars ( $M_2$ ); on the right side, the two cuspules are similar in size (ASUDAS grade 3) (see Fig. 2). On the

left second molar ( $M_2$ ), the entoconulid is somewhat smaller than the hypoconulid (ASUDAS grade 1). A small metaconulid is evident within the lingual groove between the metaconid and the entoconid on the first and second molars ( $M_1$  and  $M_2$ ) (ASUDAS grade 2).

#### *Hortus V*

There are several isolated teeth associated with Hortus V, and the age has been estimated to be 18-25 years (Lumley, 1973). The left (730) and right (988) permanent first molars ( $M_1$ ) exhibit moderate wear, heavier on the buccal than on the lingual cusps (Lumley, 1973) and dentine exposures can be observed. On the right (988), the metaconid is rather large and pyramidal. The hypoconulid is positioned buccally and distally. Five cusps are visible on the left (730) first molar ( $M_1$ ) and a small protostylid is evident within the buccal groove separating the protoconid and the hypoconid (ASUDAS grade 1). A well-developed hypoconulid is visible on the first molars ( $M_1$ ), although it is larger on the right (ASUDAS grade 3) than on the left (ASUDAS grade 2).

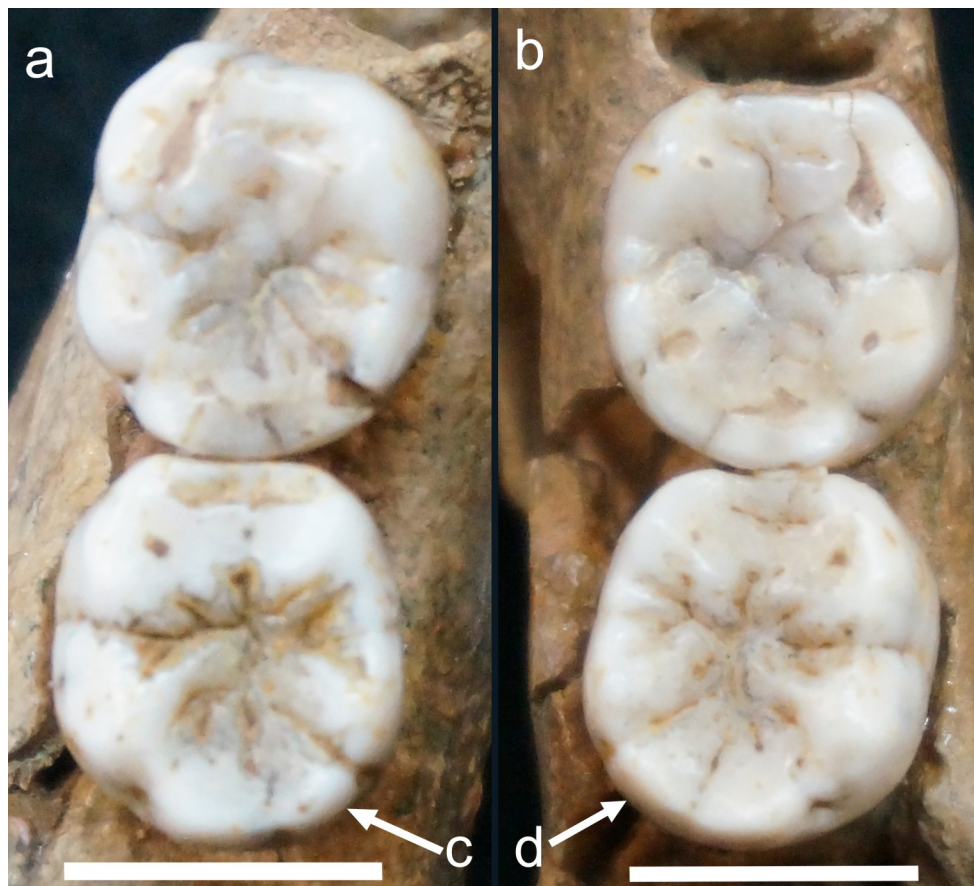


Figure 2. The left (a) and right (b) mandibular permanent first and second molars ( $M_1$  and  $M_2$ ) of Hortus IV exhibit well-demarcated anterior foveae. Variation in the development of the entoconulid (Cusp 6) is evident such that it is comparatively smaller vis-à-vis the hypoconulid on the left (c) compared to the relative size of the entoconulid on the right (d) permanent second molars ( $M_2$ ).

The left (693) second molar ( $M_2$ ) exhibits less attrition than the first molars ( $M_1$ ). Taurodont roots are present and the mesial ones are joined together as are the distal ones (Lumley, 1973). A small metaconulid is nestled within the lingual groove between the metaconid and the entoconid (ASUDAS grade 2), which is unusual on a permanent second molar (Turner et al., 1991).

The right (796) and left (695) third molars ( $M_3$ ) present a well preserved and complex morphology. A prominent anterior fovea can be observed on the right (796) third molar ( $M_3$ ), and it is positioned rather mesially (ASUDAS grade 4). A slightly smaller anterior fovea is evident on the left (695) third molar ( $M_3$ ) (ASUDAS grade 3). The right (796) third molar ( $M_3$ ) preserves a groove pattern whereby a “+” classification is evident. There are six cusps on both third molars ( $M_3$ ) and a mid-trigonid crest can be observed (ASUDAS grade 1) on the right (796) third molar ( $M_3$ ). A hypoconulid exists on both third molars ( $M_3$ ), and on the left (695) it is bifurcated and much larger (ASUDAS grade 5) than on the right (796) (ASUDAS grade 3). Both third molars exhibit an entoconulid, albeit the expression varies, such that the left (695) expression (ASUDAS grade 2) is more pronounced than the right (796) (ASUDAS grade 1). Both third molars ( $M_3$ ) also exhibit a pronounced metaconulid (ASUDAS grade 2) which is rare for this dental element (Turner et al., 1991).

#### *Hortus VI*

Hortus VI is represented by a left mandibular third molar ( $M_3$ ) from a young adult estimated to be 22-30 years (Lumley, 1973). Much of the original morphology is preserved (Lumley, 1973). An anterior fovea is present and well-defined (ASUDAS grade 3) (Lumley, 1973). A complex morphology characterizes the occlusal surface, and there are a total of six cusps, the first four of which are in close proximity to one another corresponding to the “+” classification. A weak protostylid is represented as a small fovea within the buccal groove between the protoconid and hypoconid (ASUDAS grade 1), although it is closer to the superior buccal surface of the hypoconid. A moderately sized hypoconulid is evident (ASUDAS grade 3) as is an entoconulid, represented as a small fovea on the distal edge of the occlusal surface (ASUDAS grade 3). The hypoconulid and entoconulid are similarly-sized.

#### *Hortus VIII*

Hortus VIII is a well-preserved right maxillary permanent first molar ( $M^1$ ) which has been aged to 26-34 years (Lumley, 1973). The tooth is somewhat triangular. A prominent metacone exists (ASUDAS

grade 5) that rivals the size of the strongly-pronounced hypocone (ASUDAS grade 5), and a large distal groove separates the two.

#### *Hortus XI*

The right maxillary permanent third molar ( $M^3$ ) of Hortus XI has been aged to 45-50 years (Lumley, 1973). The tooth is rectangular in shape. Striations on the occlusal, buccal, and mesial surfaces may possibly derive from paramasticatory behavior (Lumley, 1973). Much of the surface morphology has been destroyed and dentine exposures are evident on the mesial cusps. The metacone is rather small in comparison (ASUDAS grade 3). A weakly developed parastyle is evidenced as a fovea lodged within the buccal groove between the paracone and metacone (ASUDAS grade 1).

#### *Malarnaud*

Malarnaud preserves a right permanent first molar ( $M_1$ ) *in situ* and crypts for all other permanent teeth are visible, with the exception of the left third molar crown ( $M_3$ ); the right third molar ( $M_3$ ) crown can be partially observed deeply embedded within its crypt, and thus far from eruption. Malarnaud has been aged to around 14 years (Petite-Marie et al., 1971), but may be younger given the minimal wear on the right first permanent molar ( $M_1$ ). A well-developed anterior fovea is present (ASUDAS grade 3). A mid-trigonid crest is evident between the protoconid and the metaconid (ASUDAS grade 1). The cusp number is five. A deflecting wrinkle is present (ASUDAS grade 1). A buccal groove between the protoconid and metaconid can be observed (ASUDAS grade 4), although the feature does not approach the development of a protostylid with a free apex.

#### *Montmaurin*

This young adult is represented by a nearly complete mandibular corpus and has right and left permanent molars rows ( $M_1$ - $M_3$ ) in pristine condition, *in situ*, with minimal wear. The wear facets are most pronounced on the left first molar ( $M_1$ ) buccal cusps, followed by those on the right antimere. The anterior dentition and premolars are represented by crypts. A clearly demarcated anterior fovea is evident on all three molars, although on the first and second molars ( $M_1$  and  $M_2$ ) it is larger (ASUDAS grade 2), in comparison to the third molar ( $M_3$ ) (ASUDAS grade 1) (Fig. 3). The anterior fovea is accentuated further by a strongly developed mid-trigonid crest (ASUDAS grade 1) on the right and left first and second molars ( $M_1$  and  $M_2$ ), and on the left third molar ( $M_3$ ). The morphology of all the molars is complex, particularly the third molars ( $M_3$ ),

which can be described as crenulated. On the right first molar ( $M_1$ ), the groove pattern corresponds to the “Y” configuration. On the left second molar ( $M_2$ ), a “+” classification is evident, whereas on the right antimere, only the protoconid and entoconid are in contact indicative of the “X” groove pattern. There are five cusps on the first and second molars ( $M_2$  and  $M_2$ ) and the left third molar ( $M_3$ ), and four cusps on the right third molar ( $M_3$ ). A pit can be observed on the buccal surface of the protoconid of the right first molar ( $M_1$ ) (ASUDAS grade 1), and is expressed as a more pronounced groove that curves distally on the buccal surface of the protoconid of the right second molar ( $M_2$ ) (ASUDAS grade 2), though, neither can be described as a true protostylid. The hypoconulid can be characterized as large (ASUDAS grade 5), at least on the left first molar ( $M_1$ ), and, though it is present on the left second and third molars ( $M_2$  and  $M_3$ ), it is much smaller (ASUDAS grade 1). The molars on the right each exhibit a smaller hypoconulid compared to their counterparts on the left.

#### *Pech de l’Azé I*

The remains of Pech de l’Azé I include a nearly complete cranium and mandible of a young child that has been aged to between 2.5 and 3 years (Heim, 1976; Minugh-Purvis, 1988; Williams, 2013; Williams and Cofran, 2016). All of the deciduous teeth are fully erupted, although, the maxillary lateral incisors are missing postmortem. Dental attrition is minimal such that the deciduous molars preserve much of the original occlusal morphology.

Both of the maxillary deciduous first molars ( $dm^1$ ) exhibit four cusps (ASUDAS grade 4). The right and left deciduous first molars ( $dm^1$ ) exhibit a relatively small metacone, although, a free apex is present (ASUDAS grade 3). The hypocone is weakly

developed and is represented as a small ridge on the distobuccal aspect of the deciduous first molars ( $dm^1$ ) on both sides (ASUDAS grade 1).

On the deciduous second molars ( $dm^2$ ), five cusps are present. In comparison to the deciduous first molars ( $dm^1$ ), the metacone is quite large on the second molars ( $dm^2$ ) (ASUDAS grade 4). The hypocone is much larger on the deciduous second molars ( $dm^2$ ) compared to those expressed on the first molars ( $dm^1$ ). However, the left deciduous second molar ( $dm^2$ ) expresses a large hypocone (ASUDAS grade 4), while on the right antimere it is slightly smaller (ASUDAS grade 3). A prominent Carabelli’s trait is present on the deciduous second molars ( $dm^2$ ) as an independent cusp with a free apex (ASUDAS grade 7) (Fig. 4). A weak metaconule is present within the distal groove separating the hypocone and metacone on both deciduous second molars ( $dm^2$ ), although it is somewhat larger on the left (ASUDAS grade 2) than on the right (ASUDAS grade 1).

The mandible of Pech de l’Azé 1 is remarkably complete, although only on the right side are the teeth well preserved. The deciduous teeth are fully erupted with minimal attrition. The permanent first molar crown ( $M_1$ ) can be observed deeply in its crypt and the interior occlusal surface of the crown is complex.

On the right deciduous first molar ( $dm_1$ ) of Pech de l’Azé 1, an elongated and pronounced anterior fovea is evident, bordered by a prominent mesial ridge (ASUDAS grade 4). Four cusps can be observed on the right deciduous first molar ( $dm_1$ ).

The right deciduous second molar ( $dm_2$ ) exhibits a protostylid, although it is only weakly developed, consisting primarily of a raised fovea that is low and flat with a small indentation that is deep, nestled within the buccal groove separating the protoconid

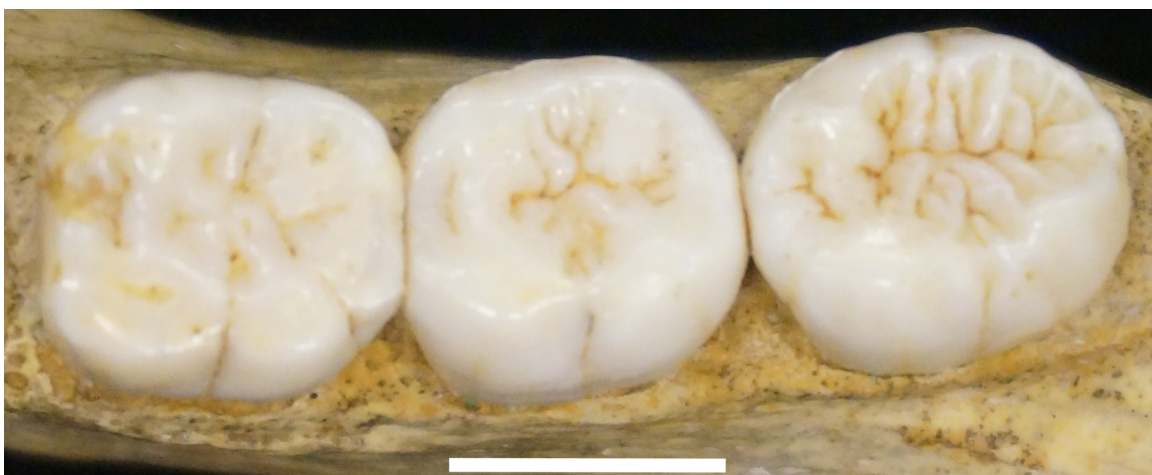


Figure 3. A well-developed, oblong anterior fovea can be observed on all left permanent molars ( $M_1$ ,  $M_2$  and  $M_3$ , from left to right) of Montmaurin, albeit its expression differs. Note the absence of the entoconulid and metaconulid (Cusps 6 and 7, respectively).



and hypoconid (ASUDAS grade 1). There are a total of five cusps evident on the right deciduous second molar ( $dm_2$ ), including a pronounced hypoconulid (ASUDAS grade 5). In addition, there is a large metaconulid with a free apex situated within the lingual groove that separates the metaconid and entoconid (ASUDAS grade 4) on the right second deciduous molar ( $dm_2$ ).

#### *Roc de Marsal*

The relatively complete skeleton of the Roc de Marsal child, has been aged to approximately three years (Heim, 1976; Minugh-Purvis, 1988; Williams, 2013; Williams and Cofran, 2016). The deciduous dentition is fully erupted, and only minimal attrition characterizes the deciduous molars. The permanent first molar crowns ( $M^1$  and  $M_1$ ) can be seen fully developed and embedded within the crypts.

On the right and left maxillary deciduous first molars ( $dm_1$ ), wear facets are visible on the hypocone. There are four cusps on both the right and left deciduous first molars ( $dm_1$ ). A large distal groove separates the metacone, which is rather small, but is represented as an independent cusplule (ASUDAS grade 2) (see Fig. 4) from the hypocone, which is poorly-developed (ASUDAS grade 1) on both deciduous first molar ( $dm_1$ ) antimeres.

On the hypocone of the deciduous second molar ( $dm_2$ ) a large wear facet is evident, stronger on the left than the right, and a deep cleft separates the hypocone and the trigone. There are five cusps evident on this dental element. These include a metacone, which is pronounced in size on the right (ASUDAS grade 5), but much smaller on the left antimeres (ASUDAS grade 3). The hypocone on the second deciduous molar ( $dm_2$ ) is larger on the left (ASUDAS grade 4) than on the right (ASUDAS grade 3). A weak metaconule exists on both deciduous second molars ( $dm_2$ ), although, like the hypocone, it is larger on the left (ASUDAS grade 2) than on the right (ASUDAS grade 1). On the deciduous second molar ( $dm_2$ ), a well-developed and independent Carabelli's cusp is evident (ASUDAS grade 7) on both sides (see Fig. 4).

Small wear facets exist on the buccal cusps of the mandibular deciduous first molars ( $dm_1$ ), although they are deeper on the right than on the left. On the deciduous first molar ( $dm_1$ ) an elongated and deep anterior fovea is present, bordered by a well-developed mesial ridge (ASUDAS grade 4) on right and left sides. On the right, the cusp number is four, whereas the left deciduous first molar ( $dm_1$ ) presents five cusps.

Similar to the mandibular deciduous first molar ( $dm_1$ ), small wear facets can be observed on the buccal cusps of the deciduous second molars ( $dm_2$ ), al-

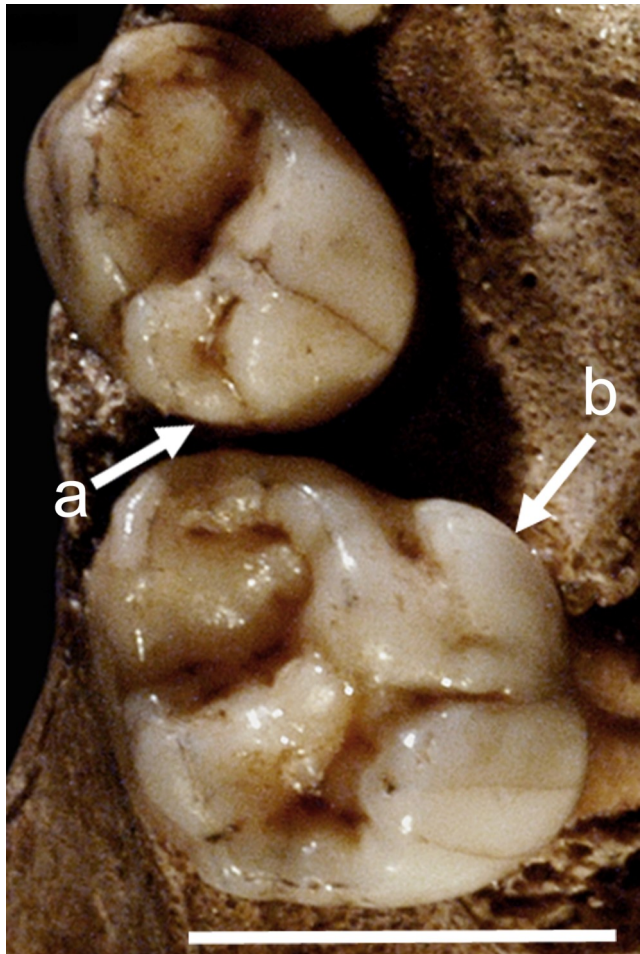


Figure 4. The Roc de Marsal right maxillary deciduous first and second molars ( $dm_1$  and  $dm_2$ ) exhibit a number of traits, including a small hypocone (a) on the deciduous first molar ( $dm_1$ ), and a pronounced Carabelli's cusp (b) on the deciduous second molar ( $dm_2$ ).

though they are more extensive on the right than the left. The metaconid central ridge is deflected in a distal direction, although, it does not reach the entoconid (ASUDAS grade 2) on the left second deciduous molar ( $dm_2$ ). On the right, the deflecting wrinkle is more weakly developed (ASUDAS grade 1). On the right deciduous second molar ( $dm_2$ ), a proto-stylid can be observed as a full cusp, represented on the buccal surface of the protoconid as a buccal groove (ASUDAS grade 6). A hypoconulid exists on right and left deciduous second molars ( $dm_2$ ). However, it is medium in size on the right (ASUDAS grade 3) and small on the left (ASUDAS grade 2). On the left deciduous second molar ( $dm_2$ ), a small metaconulid can be observed (ASUDAS grade 2).

#### *Scladina 1-4A*

Scladina 1-4A comprises right and left demi-mandibles, a right maxillary fragment as well as 11

teeth from a single older child, aged to 8 to 11 years (Smith et al., 2007, 2014; Toussaint et al. 2011, 2014; Williams, 2013; Toussaint, 2014; Williams and Cofran, 2016). The deciduous teeth examined here include the right maxillary molars ( $dm^1$  and  $dm^2$ ). Three permanent molars are also represented. These include the right maxillary second molar ( $M^2$ ) and the right mandibular first and second molars ( $M_1$  and  $M_2$ ). Scores for these teeth using the ASUDAS are reported by Toussaint (2014); the two sets of scores present more similarities than differences.

The right maxillary deciduous first molar ( $dm^1$ ) of Scladina 4A-7 is substantially worn and exhibits a small metacone (ASUDAS grade 3) (Toussaint, 2014). The cusp number of the deciduous first molar ( $dm^1$ ) is three. The right maxillary deciduous second molar ( $dm^2$ ) of Scladina 4A-5 is moderately worn (Toussaint, 2014). Dentine exposures exist on the protocone and hypocone surfaces. The metacone is larger on the deciduous second molar ( $dm^2$ ) (ASUDAS grade 4) than on  $dm^1$ . The hypocone can be described as rather large (ASUDAS grade 4) (Toussaint, 2014).

The right maxillary permanent second molar ( $M^2$ ) of Scladina 4A-3 is unerupted and the tooth crown is rectangular in shape (Toussaint, 2014). The paracone is large, and both the metacone and hypocone are present, although they differ in grade. Similar to the deciduous second molar ( $dm^2$ ), the permanent second molar ( $M^2$ ) has a well-developed metacone (ASUDAS grade 4), although the hypocone can be characterized as relatively smaller in size (ASUDAS grade 3). Between the hypocone and metacone of the permanent second molar ( $M^2$ ), a metaconule can be observed, although it is small (ASUDAS grade 3). The protocone features a small "Y" indentation on the lingual surface indicative of a rudimentary Carabelli's trait (ASUDAS grade 3).

The mandibular permanent first and second molars ( $M_1$  and  $M_2$ ) of Scladina 4A-1 are associated with the right demi-mandible. There are wear facets present on the permanent first molar ( $M_1$ ); wear is greatest on the protoconid, followed by the hypoconid. On the permanent first molar ( $M_1$ ), a fovea exists within the buccal groove separating the protoconid and the hypoconid. However, it cannot be described as a true protostylid (ASUDAS grade 1). A hypoconulid can be observed, and is rather large (ASUDAS grade 4) (Toussaint, 2014).

The permanent second molar ( $M_2$ ) is not fully erupted, and exhibits a complex occlusal morphology (Toussaint, 2014). A tall mesial ridge borders an elongated and deep anterior fovea on the permanent second molar ( $M_2$ ) (ASUDAS grade 4). The groove pattern indicative of the "+" configuration can be

discerned. There are six cusps on the second molar ( $M_2$ ), including a small hypoconulid (ASUDAS grade 2). The six cusps also include a *tuberculum sextum*, although it is substantially smaller than the hypoconulid (ASUDAS grade 1).

## ECOGEOGRAPHY

There are a number of differences in dental morphology across geographic regions (Table 2). For example, in the Mediterranean (Hortus), the metacone and hypocone are larger on maxillary deciduous and permanent first molars ( $dm^1$  and  $M^1$ ) than in the other regions. On the mandibular teeth, individuals from Hortus differ from Montmaurin of the Pyrenees in the expression of an anterior fovea, protostylid, entoconulid, and metaconulid on the permanent third molar ( $M_3$ ). The presence of a metaconule on maxillary deciduous and permanent first molars ( $dm^1$  and  $M^1$ ) is unique to the Meuse River Basin of Belgium, as is cusp number on the mandibular deciduous and permanent first molars ( $dm_1$  and  $M_1$ ). The Pyrenees and Southwest France do not exhibit any dental traits that are lacking representation in the other ecogeographic regions (Table 2).

Dental traits that are expressed in all of the ecogeographic regions include the anterior fovea on the deciduous and permanent first molars ( $dm_1$  and  $M_1$ ), which is found on a total of 16 teeth (Table 2). Additionally, a cusp number of 5+ and the presence of a hypoconulid on the deciduous and permanent second molars ( $dm_2$  and  $M_2$ ) are expressed in all ecogeographic regions (Table 2).

Dental traits that appear in the Mediterranean, Pyrenees, and the Meuse River Basin of Belgium, but not in Southwest France include the development of the protostylid and hypoconulid on the deciduous and permanent first molars ( $dm_1$  and  $M_1$ ), and a pronounced anterior fovea on the deciduous and permanent second molars ( $dm_2$  and  $M_2$ ) (Table 2). The Pyrenees and Mediterranean sites share 11 traits in common, versus five traits shared between the Mediterranean and Southwest France. The Pyrenees and Southwest France share four traits in common (Table 2).

The dental traits that distinguish ecogeographic regions include the expression of the  $M^1$  hypocone and metaconule on the maxillary molars, and the entoconulid and metaconulid on mandibular molars. The expression of the metacone, anterior fovea, and mandibular molar cusp numbers are the most similar across ecogeographic regions.

## Chronology

All of the dental features present in the older period are also found in the younger one, with the excep-

Table 2. Dental trait comparison by ecogeographical region.

Tooth type	Trait	Trait presence	Mediterranean	Meuse River Basin	Pyrenees	Southwest France
dm <sup>1</sup> & M <sup>1</sup> (n=7)	Cusp number	Score 5+		present (n=1)		
	Metacone	Score 4-5	present (n=1)			
	Hypocone	Score 4-5	present (n=1)			
dm <sup>2</sup> & M <sup>2</sup> (n=7)	Cusp number	Score 4+		present (n=1)		present (n=4)
	Metacone	Score 4-5		present (n=3)		present (n=3)
	Hypocone	Score 2-5		present (n=3)		present (n=4)
	Carabelli	Score 5-7		present (n=1)		present (n=4)
	Cusp 5	Score 1-5		present (n=1)		present (n=4)
dm <sub>1</sub> & M <sub>1</sub> (n=16)	Anterior fovea	Score 2-4	present (n=2)	present (n=1)	present (n=2)	present (n=3)
	Cusp number	Score 6+		present (n=1)		
	Mid-trigonid crest	Score 1		present (n=1)	present (n=3)	
	Protostylid	Score 1-7	present (n=1)	present (n=2)	present (n=1)	
	Cusp 5	Score 3-5	present (n=3)	present (n=1)	present (n=3)	
	Cusp 6	Score 1-5		present (n=1)		
	Cusp 7	Score 1-4	present (n=3)	present (n=1)		
dm <sub>2</sub> & M <sub>2</sub> (n=11)	Anterior fovea	Score 2-4	present (n=2)	present (n=2)	present (n=2)	
	Cusp number	Score 5+	present (n=2)	present (n=2)	present (n=1)	present (n=1)
	Mid-trigonid crest	Score 1	present (n=2)		present (n=2)	
	Protostylid	Score 1-7	present (n=1)		present (n=1)	present (n=2)
	Cusp 5	Score 1-5	present (n=2)	present (n=2)	present (n=1)	present (n=3)
	Cusp 6	Score 1-5	present (n=2)	present (n=1)		
	Cusp 7	Score 1-4	present (n=4)	present (n=1)		present (n=2)
M <sub>3</sub> (n=5)	Anterior fovea	Score 2-4	present (n=3)			
	Cusp number	Score 5+	present (n=3)		present (n=1)	
	Mid-trigonid crest	Score 1	present (n=1)		present (n=1)	
	Protostylid	Score 1-7	present (n=1)			
	Cusp 5	Score 1-5	present (n=3)		present (n=1)	
	Cusp 6	Score 1-5	present (n=3)			
	Cusp 7	Score 1-4	present (n=2)			

tion of the Hortus assemblage which lacks Carabelli's trait where it could be observed (Hortus VIII) (Table 3), corroborating de Lumley (1973). Dental features that are present in late MIS 4 and MIS 3, but absent in Scladina 1-4A, include the presence of a metaconule and a pronounced expression of the hypocone and metacone. On the maxillary deciduous and permanent second molars ( $dm^2$  and  $M^2$ ), Scladina 1-4A lacks a cusp number of 4+ and a well-developed Carabelli's feature, as noted by Toussaint (2014). The older time period also lacks more than five cusps on mandibular deciduous and permanent first molars ( $dm_1$  and  $M_1$ ), and on the mandibular deciduous and permanent second molars ( $dm_2$  and  $M_2$ ), a metaconulid is not observed. On the third mo-

lar ( $M_3$ ), Montmaurin of the older period differs from the younger Hortus remains, by lacking a pronounced anterior fovea, and any expression whatsoever of a protostylid, entoconulid, and metaconulid (Table 3).

On the maxillary molars, no obvious difference is found between older and younger periods, with the possible exception of Carabelli's trait (Table 3). The dental features which may differentiate these broad chronological categories of older and younger include the expression of the hypoconulid, the entoconulid, and metaconulid (Table 3). The dental traits that are the most similar across chronological periods include the expression of the anterior fovea and protostylid on the mandibular molars, and cusp

Table 3. Dental trait comparison by site chronology.

Tooth type	Trait	Trait presence	Older	Younger
$dm^1$ & $M^1$ (n=7)	Cusp number	Score 5+		present (n=1)
	Metacone	Score 4-5		present (n=1)
	Hypocone	Score 4-5		present (n=1)
$dm^2$ & $M^2$ (n=7)	Cusp number	Score 4+		present (n=5)
	Metacone	Score 4-5	present (n=2)	present (n=4)
	Hypocone	Score 2-5	present (n=2)	present (n=5)
	Carabelli	Score 5-7		present (n=5)
	Cusp 5	Score 1-5	present (n=1)	present (n=4)
$dm_1$ & $M_1$ (n=16)	Anterior fovea	Score 2-4	present (n=2)	present (n=6)
	Cusp number	Score 6+		present (n=1)
	Mid-trigonid crest	Score 1	present (n=3)	present (n=1)
	Protostylid	Score 1-7	present (n=2)	present (n=2)
	Cusp 5	Score 3-5	present (n=4)	present (n=3)
	Cusp 6	Score 1-5		present (n=1)
	Cusp 7	Score 1-4		present (n=4)
$dm_2$ & $M_2$ (n=11)	Anterior fovea	Score 2-4	present (n=3)	present (n=3)
	Cusp number	Score 5+	present (n=2)	present (n=4)
	Mid-trigonid crest	Score 1	present (n=2)	present (n=2)
	Protostylid	Score 1-7	present (n=1)	present (n=3)
	Cusp 5	Score 1-5	present (n=2)	present (n=6)
	Cusp 6	Score 1-5	present (n=1)	present (n=2)
	Cusp 7	Score 1-4		present (n=7)
$M_3$ (n=5)	Anterior fovea	Score 2-4		present (n=3)
	Cusp number	Score 5+	present (n=1)	present (n=3)
	Mid-trigonid crest	Score 1	present (n=1)	present (n=1)
	Protostylid	Score 1-7		present (n=1)
	Cusp 5	Score 1-5	present (n=1)	present (n=3)
	Cusp 6	Score 1-5		present (n=3)
	Cusp 7	Score 1-4		present (n=2)

number and hypocone size on the maxillary first molars (Table 3).

## DISCUSSION

### *Anterior fovea*

The anterior fovea appears with near ubiquity in the Neanderthals (Bailey, 2006), and other Pleistocene humans (Hrdlička, 1924; Turner et al., 1991). However, variation is also observed. For example, the anterior fovea is not as deep or distinct in Hortus II as is observed on Montmaurin and Malarnaud. Additionally, the anterior fovea of the first and second molars ( $M_1$  and  $M_2$ ) of Montmaurin is smaller than that observed on the first molar ( $M_1$ ) of Malarnaud. It is prominent on the deciduous first molars ( $dm_1$ ) of Pech de l'Azé 1 and Roc de Marsal. Bailey (2006) notes an inter-correlation between the presence of an anterior fovea and the mid-trigonid crest. This relationship was noted in some individuals, such as Hortus IV, Hortus V, and Montmaurin, but not others (Table 2).

### *Entoconulid and metaconulid*

The entoconulid and metaconulid, also known as Cusp 6 and Cusp 7, respectively, are routinely absent in the Pyrenees sample, whereas these accessory cusps are present in the Meuse River Basin of Belgium category (Table 2). Although the entoconulid is absent in the individuals from Southwest France, the metaconulid is present. Both of these cusps are found in Hortus for the second molars ( $M_2$ ); on the first molars ( $M_1$ ), only the metaconulid can be observed. Bailey (2006) observes rather low frequencies of Cusp 6 and Cusp 7 (20-40%), with the exception of the entoconulid in the second and third molars ( $M_2$  and  $M_3$ ), which approaches 50%. In this study, the metaconulid occurs more often than does the entoconulid.

### *Hypocone*

The hypocone of the maxillary first molars ( $dm^1$  and  $M^1$ ) differentiates the ecogeographic groupings (Table 3). This contrast is based primarily on the reduced expression of this feature in Southwest France (Pech de l'Azé 1 and Roc de Marsal) and the Meuse River Basin of Belgium (Engis 2) contrasting to the enlarged ( $M^1$ ) hypocone in Hortus VIII. Southwest France and the Meuse River Basin of Belgium are aligned in other features that suggest more similarity than expected from such distant locations. Bailey (2006) notes that the hypocone is usually present and enlarged in Neanderthals. This is certainly true of Hortus VIII who expresses a large hypocone (Lumley, 1973), but not the deciduous molars of this study.

### *Carabelli's cusp*

Carabelli's trait is noted often in this study, particularly on the deciduous second molars where its strongest expression is observed. Bailey (2006) finds that it also occurs relatively consistently in Neanderthals in both first (68%) and second molars (50%), corroborating the observations noted for Southwest France and the Meuse River Basin of Belgium, but not in Hortus (Table 2).

### *Additional considerations*

Zubov (1992) reports a prevalence of the mid-trigonid crest (epicristid) on Neanderthal mandibular molars. Only in the Pyrenees is there a consistent presence of this dental trait across the molar row; although, it is also noted in the Meuse River Basin of Belgium (see Table 2). However, it appears to be Engis 2, presumably from the younger MIS 3, rather than Scladina 1-4A (MIS 5), which exhibits a mid-trigonid crest.

Bailey (2006) reports the expression of at least five cusps on the molars is nearly ubiquitous in Neanderthals, an observation corroborated in this study (Table 2). The rarity of the expression of a deflecting wrinkle in Neanderthals (Bailey, 2006) is supported here as it is present only in Hortus II, Malarnaud, and Roc de Marsal. In addition, the "Y" groove pattern for  $M_1$  is relatively widespread in Neanderthals as reported in Bailey (2006), and is found in Engis 2, Hortus II, Scladina 1-4A, and Montmaurin. Bailey (2006) suggests the "X" groove pattern for  $M_2$  is relatively common, which in this study is expressed in Hortus IV and Montmaurin.

It is evident that the Meuse River Basin of Belgium is not distinct (Table 2), at least in the younger time period, as it shares several traits in common with Neanderthals from Southwest France. The two sites closest in proximity (Mediterranean and Pyrenees) are not the most similar, suggesting ecogeographic distance fails to account for all the differences among regions. The fact that all of the traits examined are represented in the younger category (Table 3) suggests that chronology does explain some of the variation, at least for mandibular traits, although a greater number of individuals are included in the younger category. For the maxillary molars, only Carabelli's trait differentiates the older/younger categories (Table 3).

## CONCLUSIONS

The expression of the anterior fovea is common in Neanderthals (Lumley, 1973; Bailey, 2000, 2006). It is often found on mandibular deciduous and permanent molar rows, and its presence on  $M_1$  increases the chance that it will be present on both  $M_2$  and  $M_3$

(Fig. 3). The anterior fovea is expressed on deciduous mandibular molars, such as in Pech de l'Azé 1, Roc de Marsal, and Engis 2, as is a prominent Carabelli's cusp. Other features such as the expression of the entoconulid and metaconulid are found on the permanent molars in the Hortus assemblage and in Engis 2, but not in the Pyrenees. Maxillary molar hypocone size and the presence of a metaconule differ between Mediterranean Hortus VIII on the one hand, and Southwest France and the Meuse River Basin of Belgium on the other. Montmaurin and Malarnaud from the Pyrenees region resemble one another in the expression of traits on mandibular M<sub>1</sub> and are dissimilar to Scladina 1-4A. Likewise, Hortus II and Hortus IV resemble one another, although Hortus II and Hortus V are younger (Phase V) than Hortus IV (Phase IV) (Lumley, 1973). However, they are not identical, and Hortus IV and Hortus V also share traits to the exclusion of Hortus II, suggesting ecogeography alone does not account for the variation in the expression of dental features. Chronology may account for the absence in MIS 7 to 5 of 6+ cusps in mandibular molars, the expression of a well-developed entoconulid and metaconulid, and a pronounced Carabelli's feature, all of which are observed in late MIS 4/MIS 3.

#### ACKNOWLEDGMENTS

It is with much gratitude that the following curators are thanked for their permission to examine the Neanderthal fossils featured here: Aurélie Fort and Liliana Huet, Musée de l'Homme; Marie-Antoinette de Lumley, Gaël Becam, and Tony Chevalier, Centre Européen de Recherches Préhistoriques de Tautavel; Jean-Jacques Cleyet-Merle, Musée National de Préhistoire Les Eyzies-de-Tayac; Valentin Fischer, Université de Liège, and Dominique Bonjean and Michel Toussaint, Scladina Cave Archaeological Centre. The image utilized in Figure 4 featuring Roc de Marsal belongs to the collections of the Musée National de Préhistoire, les Eyzies, Dordogne, France, and was used with the permission of Jean-Jacques Cleyet-Merle. Funding for this project was received by Fulbright-Belgium and the Commission for Educational Exchange between the United States, Belgium, and Luxembourg.

#### LITERATURE CITED

- Bailey S.E. (2000). Dental morphological affinities among late Pleistocene and recent humans. *Dental Anthropology*, 14, 1–8.
- Bailey S.E. (2002). A closer look at Neanderthal post-canine dental morphology. I. The mandibular dentition. *Anatomical Record*, 269, 148–156.
- Bailey S.E. (2004). A morphometric analysis of maxillary molar crowns of Middle-Late Pleistocene hominins. *Journal of Human Evolution*, 47, 183–198.
- Bailey S.E. (2006). Beyond shovel-shaped incisors: Neandertal dental morphology in a comparative context. *Periodicum Biologorum*, 108, 253–267.
- Crégut-Bonnoure É., Boulbes N., Guérin C., Pernaud J., Tavoso A., Cammas R. (2010). Le contexte géomorphologique et faunique de l'homme de Montmaurin (Haute-Garonne). *Préhistoires Méditerranéennes*, 1, 35–85.
- Di Modica K., Toussaint M., Abrams G., Pirson S. (2016). The Middle Palaeolithic from Belgium: chronostratigraphy, territorial management and culture on a mosaic of contrasting environments. *Quaternary International*, 411, 77–106.
- Guérin G., Discamps E., Lahaye C., Mercier N., Guibert P., Turq A., Dibble H.L., McPherron S.P., Sandgathe D., Goldberg P., Jain M., Thomsen K., Patou-Mathis M., Castel J.-C., Soulier M.-C. (2012). Multi-method (TL and OSL), multi-material (quartz and flint) dating of the Mousterian site of Roc de Marsal (Dordogne, France): correlating Neanderthal occupations with the climatic variability of MIS 5-3. *Journal of Archaeological Sciences*, 39, 3071–3084.
- Hanihara K. (1961). Criteria for classification of crown characters of the human deciduous dentition. *Journal of the Anthropological Society of Nippon*, 69, 27–45.
- Heim J.-L. (1976). Les Néandertaliens en Périgord. In H. de Lumley (Ed.), *La préhistoire Française. Tome I: Les civilisations Paléolithiques et Mésolithiques de la France* (pp. 578–583). Paris: Éditions du CNRS.
- Hrdlička A. (1924). New data on the teeth of early man and certain fossil European apes. *American Journal of Physical Anthropology*, 3, 109–132.
- Hublin J.-J., Roebroeks W. (2009). Ebb and flow or regional extinctions? On the character of Neandertal occupation of northern environments. *Comptes Rendus Palevol*, 8, 503–509.
- Hublin J.-J., Bailey S., Olejniczak A., Smith T., Verna C., Sbihi-Alaoui F.Z., Zouak M. (2012). Dental evidence from the Aterian human populations of Morocco. In J.-J. Hublin & S. McPherron (Eds.), *Modern origins: A North African perspective* (pp. 189–204). Dordrecht: Springer.
- Kelso J., Prüfer K. (2014). Ancient humans and the origin of modern humans. *Current Opinion in Genetics and Development*, 29, 133–138.
- Lalueza-Fox C., Rosas A., Estalrich A., Gigli E., Campos P.F., García-Taberner A., García-Vargas S., Sánchez-Quinto F., Ramírez O., Civit S., Bastir M., Hugnet R., Santamaría D., Gilbert M.T.P., Willerslav E., de la Rasilla M. (2011). Genetic evidence for patrilocal mating behavior

- among Neandertal groups. *Proceedings of the National Academy of Sciences USA*, 108, 250–253.
- Lumley M.-A. de. (1973). *Anténéandertaliens et Néandertaliens du bassin méditerranéen occidental européen*. Marseille: Université de Provence.
- Lumley M.-A. de. (1976). Les Néandertaliens dans le Midi méditerranéen. In H. de Lumley (Ed.), *La préhistoire Française. Tome I: Les civilisations Paléolithiques et Mésolithiques de la France* (pp. 567–577). Paris: Éditions du CNRS.
- Minugh-Purvis N. (1988). *Patterns of craniofacial growth and development in Upper Pleistocene hominids*. (Ph.D. dissertation), University of Pennsylvania, Philadelphia, PA.
- Patte E. (1959). La dentition des Néandertaliens. *Annales de Paléontologie*, 45, 1–162.
- Petite-Marie N., Ferebach D., Bouvier J.-M., Vandermeersch B. (1971). France. In K.P. Oakey, B.G. Campbell & T.I. Molleson (Eds.), *Catalogue of fossil hominids. Part II: Europe* (pp. 71–187). London: Trustees of the British Museum (Natural History).
- Pirson S., Court-Picon M., Dambon F., Balescu S., Bonjean D., Laesarts P. (2014). The palaeoenvironmental context and chronostratigraphic framework of the Scladina Cave sedimentary sequence (Units 5 to 3 sup). In M. Toussaint & D. Bonjean (Eds.), *The Scladina 1-4A juvenile Neandertal (Andenne, Belgium): Palaeoanthropology and context* (pp. 69–92). Andenne, Belgium: Études et Recherches Archéologiques de l'Université de Liège.
- Semal P., Toussaint M., Maureille B., Rougier H., Crevecoeur I., Balzeau A., Bouchneb L., Louryan S., De Clerck N., Rausin L. (2005). Numérisation des restes humains néandertaliens belges. Préservation patrimoniale et exploitation scientifique. *Notae Praehistoricae*, 25, 25–38.
- Semal P., Rougier H., Crevecoeur I., Jungels C., Flas D., Hauzeur A., Maureille B., Germonpré M., Bocherens H., Pirson S., Cammaert L., De Clerk N., Hambucken A., Higman T., Toussaint M., van der Plicht J. (2009). New data on the late Neandertals: direct dating of the Belgian Spy fossils. *American Journal of Physical Anthropology*, 138, 421–428.
- Smith T.M., Toussaint M., Reid D.J., Olejniczak A.J., Hublin J.-J. (2007). Rapid dental development in a Middle Paleolithic Belgian Neanderthal. *Proceedings of the National Academy of Sciences USA*, 104, 20220–20225.
- Smith T.M., Reid D.J., Olejniczak A.J., Tafforeau P.T., Hublin J.-J., Toussaint M. (2014). Dental development in and age at death of the Scaldina 1-4A juvenile Neandertal. In M. Toussaint & D. Bonjean (Eds.), *The Scladina 1-4A juvenile Neandertal (Andenne, Belgium): Palaeoanthropology and context* (pp. 155–166). Andenne, Belgium: Études et Recherches Archéologiques de l'Université de Liège.
- Soressi M., Jones H.L., Rink W.J., Maureille B., Tillier A.-M. (2007). The Pech-de-l'Azé I Neandertal child: ESR, uranium series and AMS 14C dating of its MTA type B context. *Journal of Human Evolution*, 52, 455–466.
- Tillier A.-M. (1983). Le crâne d'enfant d'Engis 2: un exemple de distribution des caractères juvéniles, primitifs et néandertaliens. *Bulletin Société royale belge d'Anthropologie et de Préhistoire*, 94, 51–75.
- Toussaint M. (2014). The dentition of the Scladina 1-4A juvenile Neandertal. In M. Toussaint & D. Bonjean (Eds.), *The Scladina 1-4A juvenile Neandertal (Andenne, Belgium): Palaeoanthropology and context* (pp. 233–306). Andenne, Belgium: Études et Recherches Archéologiques de l'Université de Liège.
- Toussaint M., Semal P., Pirson S. (2011). Les Néandertaliens du bassin mosan belge: bilan 2006–2011. In M. Toussaint, K. Di Modica & S. Pirson (Eds.), *Le Paléolithique moyen de Belgique. Mélanges Marguerite Ulrix-Closset* (pp. 149–196). Liège: Études et Recherches archéologiques de l'Université de Liège, 128, Les Chercheurs de la Wallonie. Hors-série 4.
- Toussaint M., Bonjean D., Pirson S. (2014). The Scladina 1-4A juvenile Neandertal: a synthesis. In M. Toussaint & D. Bonjean (Eds.), *The Scladina 1-4A juvenile Neandertal (Andenne, Belgium): Palaeoanthropology and context* (pp. 409–418). Andenne, Belgium: Études et Recherches Archéologiques de l'Université de Liège.
- Turner C., Nichol C., Scott G. (1991). Scoring procedures for key morphological traits of the permanent dentition: The Arizona State University Dental Anthropology System. In M. Kelley & C. Larsen (Eds.), *Advances in Dental Anthropology* (pp. 13–31). New York: Wiley Liss.
- Twisselmann F. (1971). Belgium. In K.P. Oakey, B.G. Campbell & T.I. Molleson (Eds.), *Catalogue of fossil hominids. Part II: Europe* (pp. 5–13). London: Trustees of the British Museum (Natural History).
- Williams F.L. (2013). Neandertal craniofacial growth and development and its relevance for modern human origins. In F. Smith F & J. Ahern (Eds.), *The origins of modern humans: Biology reconsidered* (pp. 253–284). Hoboken, NJ: Wiley.
- Williams FL, Cofran Z. (2016). Postnatal craniofacial ontogeny in Neandertals and modern humans. *American Journal of Physical Anthropology*, 159, 394–409.
- Zubov A.A. (1992). The epicristid or middle trigonid crest defined. *Dental Anthropology. Newsletter*, 6, 9–10.

## Severe Plane-Form Enamel Hypoplasia in a Dentition from Roman Britain

Ian Towle<sup>1\*</sup>, Eleanor R. Dove<sup>1</sup>, Joel D. Irish<sup>1,2</sup>, Isabelle De Groot<sup>1</sup>

<sup>1</sup>Research Centre in Evolutionary Anthropology and Palaeoecology, School of Natural Sciences and Psychology, John Moores University, Liverpool, United Kingdom

<sup>2</sup>Evolutionary Studies Institute and Centre for Excellence in PaleoSciences, University of the Witwatersrand, Private Bag 3, WITS 2050, South Africa

**Keywords:** Romano-British, dental enamel, dental defects

**ABSTRACT** Enamel defects can provide insight into the life histories of past individuals and populations, including information on a wide range of disturbances during childhood. This study investigates a particularly severe case of plane-form enamel hypoplasia from a Roman site in Gloucester, UK. Dentine protrudes above the occlusal enamel of upper central incisors, both upper canines, the lower left canine, lower right central incisor, and all four first molars. Given the morphology and location of these defects, along with the developmental timing of the affected teeth, such factors as molar-incisor hypomineralization, amelogenesis imperfecta, and congenital syphilis can likely be ruled out. The defects resulted from a nonspecific but severe physiological disturbance during the second year of life. Severe plane-form defects of this kind, where enamel formation has completely ceased, are extremely rare in premodern populations, and this example is one of the earliest reported cases. It has been suggested that these defects generally occur only in individuals that survived a life-threatening illness, which would explain the scarcity in the archaeological record, i.e., the afflicted individual would not have lived long enough for the defects to manifest. Comparisons with clinical examples and pathogen DNA analysis may provide further insight into the etiology of these defects.

Enamel hypoplasia is found in both modern and archaeological samples, in various forms and with different etiologies (e.g., Goodman et al., 1987; Lukacs et al., 2001; Guatelli-Steinberg et al., 2004; Ogden et al., 2007; Xing et al., 2015; Rohnbogner and Lewis, 2016). A range of causes can yield similar defects, making diagnosis in archaeological cases difficult. These defects nonetheless can often give insight into past populations, and further our understanding of health, diet, genetic disorders, and environmental stresses (Moggi-Cecchi et al., 1994; Hillson et al., 1998; Cunha et al., 2004; Crawford et al., 2007; Schuur, 2012; Guatelli-Steinberg et al., 2014). In this study, we investigate an exceptionally severe case of plane-form enamel hypoplasia in a dentition recovered from a Roman mass grave in Gloucester, UK. Comparisons are made with other archaeological examples as well as modern clinical case studies.

The affected individual was found in a mass grave containing 15 subadults and 76 adults, at a Roman site in Gloucester, UK (Simmonds et al., 2008). The remains were radiocarbon dated to the 1<sup>st</sup> to 2<sup>nd</sup> century AD. A multi-isotopic investigation was subsequently carried out by Chenery et al. (2010) on a sample of the skeletal remains, with results suggesting the grave consisted of a cross-section of the Gloucester population. Results are

also indicative of diverse geographic origins for these individuals, whose diet was predominately terrestrial like that from other British Roman sites. The remains within the grave show no evidence of violence, and it has been suggested that they may be victims of an epidemic. Due to the time they could have been victims of the Antonine plague (Simmonds et al., 2008; Chenery et al., 2010).

Plane-form enamel hypoplasia, or PFEH, occurs when enamel matrix formation ceases entirely or in part, resulting in areas of an affected crown with little or no enamel deposition (Hillson and Bond, 1997; Ogden et al., 2007; Sawada et al., 2008; Krenz-Niedbala and Kozłowski, 2013). These defects have been described as extreme furrow-form defects, with one perikyma widened markedly. This exposed space comprises the large area of enamel matrix that was developing at the time and commonly displays Tomes process pits (Hillson, 2014). In rare circumstances the whole plane of the brown stria can be exposed down to the

\*Correspondence to:

Ian Towle

Research Centre in Evolutionary Anthropology and Palaeoecology, School of Natural Sciences and Psychology,  
e-mail: I.Towle@2014.ljmu.ac.uk



dentine surface; as noted by Hillson (2014), if such a defect occurs while the cusps are still forming, all of the above layers of matrix will be affected. Therefore, a relatively short, i.e., acute period of severe stress can potentially lead to a very large defect.

### MATERIALS AND METHODS

The individual (Skeleton 1672) was recovered from a lower layer of the pit, and consists only of a fragmented skull, fragments of all cervical vertebrae and thoracic vertebral bodies, a rib fragment, and the left medial cuneiform; no pathological lesions are visible on these elements. The mandible and maxilla are fragmentary but otherwise well preserved – though all second and third molars are missing postmortem. Based on the morphology of the glabella and supraorbital ridge of the cranium, the individual was probably female (Walker, 2008). She would have been between 15-18 years of age at death (Simmonds et al., 2008). All material is housed at Liverpool John Moores University.

The dentition was first examined macroscopically, with a 10x hand lens used during the differential diagnosis to help confirm or discount conditions; further descriptions were based on images acquired using SEM. Each tooth was examined separately and any enamel defects were recorded and described. Other dental pathological conditions were also noted.

### RESULTS

Enamel is completely or mostly absent near and on the occlusal surface of the upper central incisors, all first molars, upper canines, left lower canine, and right lower central incisor (Figs. 1 and 2). Dentine is exposed as an “island” above the surrounding enamel, and is clearly the result of an enamel defect at the time of for-

mation rather than dental wear (Fig. 3). This is supported by the fact that the teeth most affected (first molars and upper central incisors) show negligible enamel wear and no evidence of weak or hypomineralisation/hypocalcification enamel. Cervical to these defects the enamel immediately returns to normal and remains so on the rest of the crown surface.

The upper central incisors are most affected in terms of surface area, with PFEH across nearly the entire incisal edge. Only the mesial and distal extremities are not involved (Fig. 2A, B). The enamel located cervical to this defect appears normal and the overall tooth morphology does not evidence other abnormalities (Fig. 3). On the left central incisor, the defect is slightly more pronounced. The distance from the cementum enamel junction (CEJ) to the start of the defect (i.e. length of the normal enamel) is 7.95mm and from the CEJ to the top of the exposed dentine, 9.40mm; therefore, the defect depth is a maximum of 1.45mm. Both measurements are from the center of the labial surface, where the exposed dentine is at its widest. The same measurements for the right incisor are 7.96mm, 9.27mm, and 1.31mm, respectively.

After the upper central incisors, the most affected teeth are the first molars. All have PFEH defects around the cusps (Fig. 2D, E, F). In the upper first molars the two distal cusps appear slightly more affected with more dentine exposed; in the lower counterparts the mesial buccal cusp appears slightly less affected. However, in both cases it should be emphasized that the exposed occlusal dentine is worn so a full assessment of the original morphology cannot be inferred.

Both upper canines have a distinct groove just below the cusp, with dentine exposed above. It is a PFEH defect, but because of wear the original extent is un-

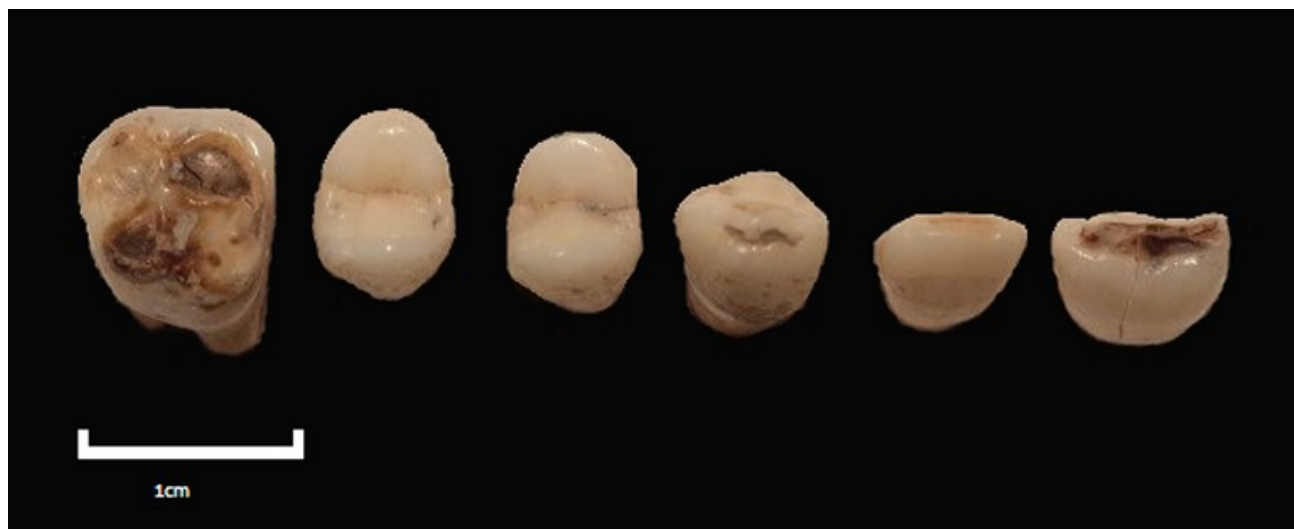

Figure 1. Occlusal view of the upper left permanent teeth of Skeleton 1672. From left to right: first molar, second premolar, first premolar, canine, lateral incisor and central incisor.

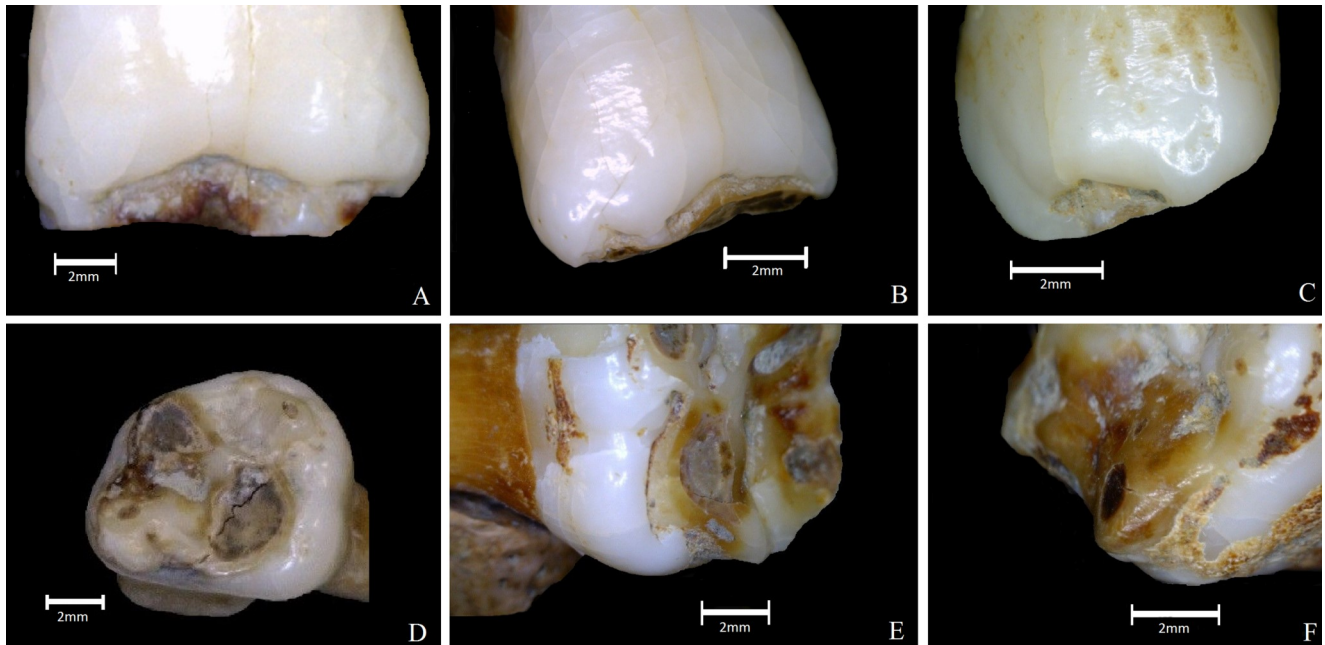


Figure 2. Teeth displaying plane-form enamel hypoplasia defects. (A) Upper left central incisor, labial view. (B) Upper right central incisor, labial view. (C) Upper right canine, labial view. (D) Upper left first molar, occlusal view. (E) Upper right first molar, lingual view. (F) Lower right first molar, mesial/lingual corner.




Figure 3. SEM of the upper right central incisor. (A) Showing the sharp contrast between the dentine on the occlusal surface and the enamel above. (B) A zoomed in view of the same surface to compare the textural differences between the surfaces. Note, post-mortem cracks on crown surface.

known. Under close inspection pitting enamel hypoplasia is evident on the mid-crown of the buccal sides, cervical to the PFEH (see Fig. 2C). The lower left canine is similarly affected but no defects were found on the lower right canine, likely due to wear.

The lower right central incisor has a PFEH defect toward the occlusal surface with dentine exposed, but to a lesser extent than the upper central incisors. The lower left central incisor does not display a defect;

however, wear may have erased the evidence.

Extensive enamel pitting is present on the upper second premolars, particularly the lingual surface (Fig. 4A, B, C). These are mainly uniform small depressions that extend across the entire side, except near the CEJ. The buccal surface is also affected but the pitting is not as defined or uniform. Upper first premolars also exhibit pitting, but it is less defined than on the second premolars; again, they are more

noticeable on the lingual surface. The lower premolars exhibit pitting, but is not overtly defined, i.e., it is barely discernible without use of the 10x lens.

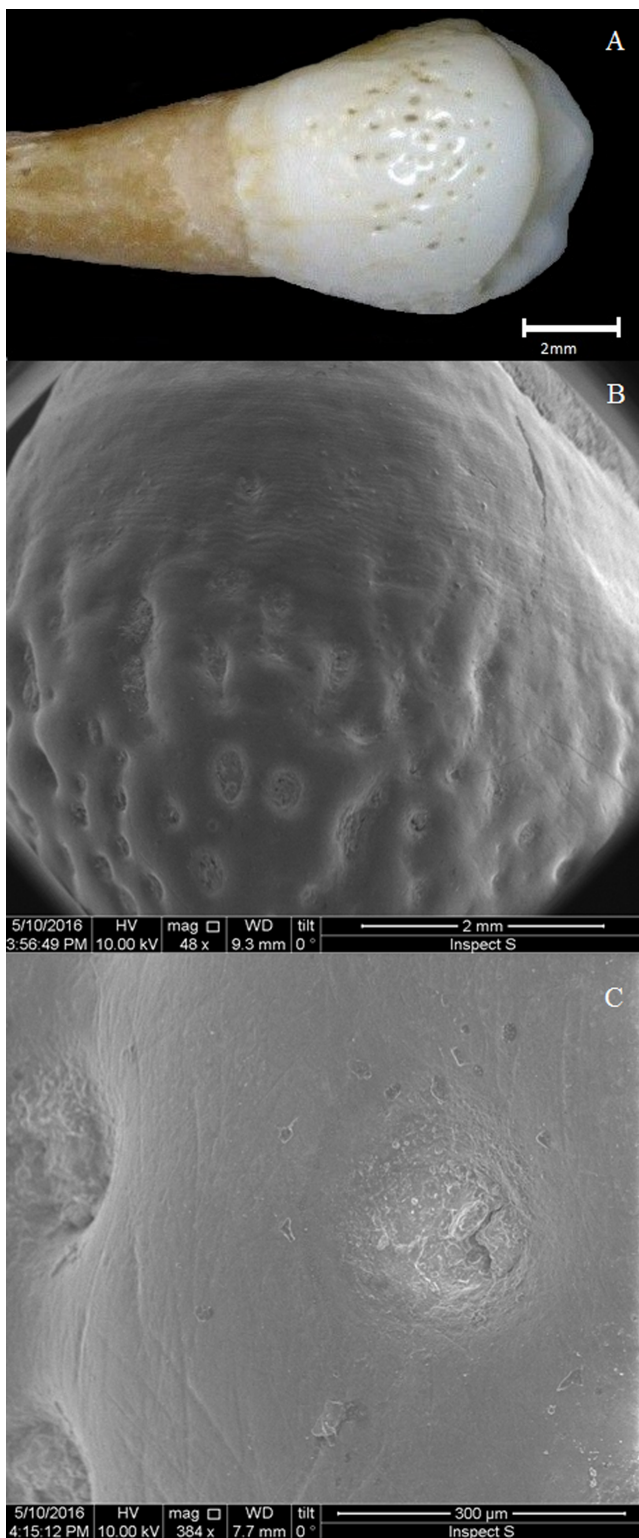


Figure 4. Pitting enamel hypoplasia on the upper left second premolar, lingual surface. (A) Photograph of whole tooth. (B) SEM showing pitting and perikymata underneath. (C) Close-up SEM of one pit.

Although it is difficult to estimate the age at formation of PFEH defects (Hillson, 2014), it is possible to provide a rough estimate in this case due to multiple teeth sharing the defect across cusps. Using the chronological ages of enamel formation by Reid and Dean (2000, 2006) it was calculated that the defects on the central upper incisors, first molars, and canines fit with an episode of stress between 1 and 1.5 years of age (Fig. 5). The overlap in formation times and similarity in appearance indicate that these defects occurred concurrently, so were most likely caused by the same etiology. After about 1.6 years of age the enamel-forming process returned to normal. It has been suggested that pitting enamel hypoplasia position on the crown may be only loosely related to timing of the disturbance (Hillson and Bond, 1997). However, the minimum age that this pitting could have formed on the upper premolars is at least one year after formation of the PFEH defects on the other teeth (Holt et al., 2012), so it certainly resulted from a later episode.




Figure 5. Upper right central incisor overlain with Reid and Dean (2000) chronological age of enamel formation, giving an estimate to the age the plane-form defect occurred.

Pathological porosity within the observable mandibular alveoli may be suggestive of chronic infection. However, postmortem damage makes the full extent of this porosity difficult to understand. Radiographs do not show obvious large abnormalities nor evidence of abscess. Calculus is present on all teeth [1-2 in severity according to Brothwell (1981)]. The upper lateral incisors appear normal in morphology and enamel structure across the entire crown. Thus, the affected teeth suggest the disturbance responsible for the

PFEH occurred in the second year of the individual's life, and was likely caused by a single exceptional episode.

### DIFFERENTIAL DIAGNOSIS

Although PFEH is visible on multiple teeth, the relatively light occlusal wear means that the original scope of the hypoplasia may be erased to some degree, e.g., the lower right canine and lower central incisor. However, in the majority of teeth affected it is only the dentine that is worn, with the enamel relatively unworn even towards the occlusal surface. The pitting that is most defined and prevalent on the upper premolars is not found on teeth affected by PFEH, with the exception of the upper canines. The reason may relate to differences in formation and morphology between tooth classes and/or the location on the crown; however, it is also possible that two separate causes account for these alternate hypoplastic defects, or at least a change in severity.

#### Amelogenesis Imperfecta

There are several types of hereditary hypoplastic amelogenesis imperfecta and forms can vary among individuals (Wright, 1985; Aldred et al., 2003). It is rare, e.g., affecting one in every 700 to 14,000 people (Sundell and Koch, 1984; Crawford et al., 2007). Enamel pitting, thinning, and PFEH are all associated with this condition (Mardh et al., 2002; Aldred et al., 2003; Schuurs, 2012). However, thinning of enamel across the entire crown has also been reported, and all teeth may be affected regardless of formation time. This combination is not evident in the Roman dentition, i.e., sharp contrasts occur between defect and the enamel beneath. The age of defect formation also does not support this etiology. Superficially, the pitting looks like published examples of certain amelogenesis imperfecta types. However, this pitting is not found on the teeth with PFEH defects, except the canines, and these two defect types are usually associated with different types of amelogenesis imperfecta (Schuurs, 2012).

#### Molar incisor hypomineralisation

Another form of hypoplasia classified in recent years is molar incisor hypomineralisation (MIH) (Weerheijm, 2003; Ogden et al., 2007). This condition alters the translucency of enamel, which is of normal thickness but brown, white, or yellow in color (Weerheijm, 2003). It is included in this differential diagnosis because in some cases post-eruptive breakdown of enamel, which becomes soft and porous, can occur (Lygidakis et al., 2008). Although fitting this condition, in that the central incisors and first molars are most severely affected, it is unlikely that MIH is the cause. The defining enamel surface opacities are absent and the substantial areas of missing enamel appear to have been caused at the

time of formation (see Fig. 3).

#### Congenital syphilis

It is difficult to diagnose congenital syphilis in archaeological material for many reasons, including contradictions in the original descriptions, lack of reference material, and high variability in form (Hillson et al., 1998; Ioannou et al., 2015). Defects in this individual are in the correct location and fit the description of PFEH in the mulberry molar form of congenital syphilis, i.e., a clear PFEH defect cuts sharply across the base of the cusps (Fournier, 1884; Putkonen, 1963; Hillson et al., 1998). Congenital syphilis also commonly affects the same teeth noted in this study. A PFEH defect is present around the tip of two canines, which is also a characteristic (Fournier, 1884; Hillson et al., 1998).

Nevertheless, there are several reasons to reject a congenital syphilis diagnosis. First, the most characteristic feature is absent – Hutchinson's incisors. The incisal edges of the upper incisors are not shortened, and no characteristic notches or bulging on the distal or mesial surfaces occur. The first molars do not evidence features associated with Moon's molars, i.e., abnormal cusp spacing or crown side bulging. As mentioned, mulberry molars do show PFEH defects, but are usually associated with a change in cuspal morphology not found here. However, not all cases of congenital syphilis possess these diagnostic features (Putkonen, 1963). Hillson et al. (1998) notes that PFEH defects in individuals with mulberry molars can also be caused by a range of other factors, so cannot be used in isolation to diagnose an archaeological case. A lack of definitive evidence for the presence of syphilis in England at this time also makes such a possibility unlikely.

It is worth noting that ingestion of high levels of a toxic compound such as mercury during the developmental period can result in PFEH (Ioannou et al., 2015). Mercury was used extensively in recent times to treat illnesses, particularly those affecting the skin like congenital syphilis and leprosy; however, at present there is little evidence that mercury was used to treat illnesses in Roman Britain.

Plane-form enamel hypoplasia with nonspecific cause Hillson and Bond (1997) demonstrate that PFEH defects occur when a plane of a brown stria of Retzius is left wholly or partially exposed, leading to a sharp step on the cervical edge of the defect where normal enamel formation resumes. Such cases can affect multiple striae of Retzius, leading to a step appearance near the occlusal surface. The latter is not evident in the present specimen; rather, a marked step directly below the defect is present in all affected teeth, followed by normal enamel along the rest of the crown height. Therefore, the episode that initiated the defect was likely of short duration.

## DISCUSSION AND CONCLUSIONS

By far the most common enamel hypoplasia defect is linear in form, with rates in populations varying substantially (Guatelli-Steinberg, 2015). In this Roman Gloucester site 28.5% of all teeth exhibit linear enamel hypoplasia (LEH) (Simmonds et al., 2008). Pitting is less common, though it is regularly reported in archaeological remains within LEH bands or scattered across the crown in a range of shapes and sizes (Ogden et al., 2007; Guatelli-Steinberg, 2015). It is unclear why in some cases pitting and others LEH occurs (Lovell and Whyte, 1999). PFEH is, in contrast, rare, which may in part be due to researchers simply including it as LEH (e.g., Goodman et al., 1987); however, the primary reason is likely related to high mortality rates in individuals who experienced circumstances that caused the defects. Occlusal wear also likely reduces the true number of cases observable in the archaeological record.

Although severe PFEH has not been described in remains from Roman Britain before, there is extensive literature on developmental defects, and more generally bioarchaeological research, for this time period (e.g., Simmonds et al., 2008; Pitts and Griffin, 2012; Redfern et al., 2015; Rohnbogner & Lewis, 2016). The overall diet of individuals in Roman Britain would likely have been much broader than earlier periods, and there was variation in the foods eaten based on the site, sex, social status, and cultural background of each individual (King, 1999; Cool, 2006; van der Veen, 2008; Rohnbogner & Lewis, 2016). Additionally, a variety of diseases and illnesses have been described in populations from this time period (Roberts and Cox, 2003; Lewis, 2010; Redfern et al., 2015). Therefore, the relatively high rates of enamel hypoplasia in Roman British populations may relate to a variety of factors, yet the example presented in this case study stands out due to its severity. This may reflect a more severe episode than those in other individuals with LEH defects, or may be due to a different etiology. However, either way what is noteworthy is this individual went on to survive for well over a decade after these defects formed. Perhaps therefore the lack of such defects in the archaeological record also reflects the fact extensive care is needed for an individual to overcome such a disturbance event.

Although PFEH defects have been reported in earlier fossil and archaeological hominins, they have either not been severe or the process of formation has been different, with localized hypoplasia often referred to as a PFEH defect (see Skinner et al., 2016). We differentiate between PFEH and localized hypoplasia because it is clear that in this case the defects

are systemic. There are clear PFEH in some individuals dated to medieval times, in which congenital syphilis was suggested to be the cause (e.g., Lauc et al., 2015; Ioannou et al., 2015). Witzel et al. (2008) also present cases of PFEH in a medieval sample, but they are of a lesser severity with the dentine not exposed. Other more recent examples also exist, either caused by congenital syphilis or other physiological disturbance (e.g., Karnosh, 1926; Boyde, 1970; Hillson and Bond, 1997; Lambert, 2006; Ogden et al., 2007). However, it is clinical studies that offer the best comparative examples [e.g., Figure 3 of Wong (2014)].

A potential example that predates the case study presented here is from a Neolithic individual from present day Japan (Sawada et al., 2007). This individual shows extensive plane-form defects that superficially resemble those in this study. The main differences between the defects described in their study and the one presented here are that the Neolithic example has enamel hypocalcification involvement and no exposed dentine.

Karnosh (1926) highlights defects on anterior teeth of individuals without congenital syphilis; one is a PFEH defect with all properties seen in the present individual. These defects were thought by the author to have been caused by nutritional upset and acute infections. Similar defects were thought by Boyde (1970) to result from major disturbances in metabolism. It has been suggested that such a severe defect, where enamel formation ceases completely, would result from two or more combined stresses (Hillson, 2005). In any case, it is clear that severe illness or other episode of non-specific physiological stress is needed (Ogden et al., 2007; Guatelli-Steinberg, 2015). The fact the enamel cervical to the PFEH returns to normal so sharply suggests that the individual may have quickly recovered from this episode. However, the enamel pit defects on later developing teeth suggest continued poor health in childhood after the initial, severe illness. The potential for a chronic infection in the maxilla and mandible may also hint at this individual's continued poor health after eruption of her permanent teeth; however, it cannot be determined if these three separate defects and other pathologies have the same etiology.

In sum, we have described one of the earliest known examples of severe PFEH, in which enamel did not form over large parts of the crown in multiple teeth. Although a specific etiology could not be established, we did rule out three potential causes: amelogenesis imperfecta, molar incisor hypomineralisation, and congenital syphilis. Clearly, this individual was exposed to a serious disturbance during development, and when more examples of this type of defect are described in the literature a better understanding

of plane-form hypoplasia can be explored. Mercury testing, pathogen DNA analysis, and comparisons with a larger database of modern clinical examples should provide further evidence regarding the etiology of these defects.

#### ACKNOWLEDGMENTS

We would like to thank Paul Gibbons for access and help with the SEM and The Museum of Gloucester for access and support in studying the skeletal collection housed at Liverpool John Moores University.

#### LITERATURE CITED

- Aldred, M., Savarirayan, R., & Crawford, P. (2003). Amelogenesis imperfecta: A classification and catalogue for the 21st century. *Oral Diseases*, 9, 19-23.
- Boyde, A. (1970). The surface of the enamel in human hypoplastic teeth. *Archives of Oral Biology*, 15, 897-898.
- Brothwell, D. R. (1981). *Digging up bones: The excavation, treatment, and study of human skeletal remains*. Ithaca: Cornell University Press.
- Chenery, C., Mueldner, G., Evans, J., Eckardt, H., & Lewis, M. (2010). Strontium and stable isotope evidence for diet and mobility in Roman Gloucester, UK. *Journal of Archaeological Science*, 37, 150-163.
- Cool, H. E. (2006). *Eating and drinking in Roman Britain*. Cambridge: Cambridge University Press.
- Crawford, P. J., Aldred, M., & Bloch-Zupan, A. (2007). Amelogenesis imperfecta. *Orphanet Journal of Rare Diseases*, 2, 17.
- Cunha, E., Rozzi, F. R., Bermúdez de Castro, J., Martínón-Torres, M., Wasterlain, S., & Sarmiento, S. (2004). Enamel hypoplasias and physiological stress in the Sima de los Huesos Middle Pleistocene hominins. *American Journal of Physical Anthropology*, 125, 220-231.
- Fournier, A., & White, J. W. (1884). *Syphilitic teeth*. SS White Dental Manufacturing Company.
- Goodman, A. H., Allen, L. H., Hernandez, G. P., Amador, A., Arriola, L. V., Chavez, A., & Pelto, G. H. (1987). Prevalence and age at development of enamel hypoplasias in Mexican children. *American Journal of Physical Anthropology*, 72, 7-19.
- Guatelli-Steinberg, D., Larsen, C. S., & Hutchinson, D. L. (2004). Prevalence and the duration of linear enamel hypoplasia: a comparative study of Neandertals and Inuit foragers. *Journal of Human Evolution*, 47, 65-84.
- Guatelli-Steinberg, D., Stinespring-Harris, A., Reid, D. J., Larsen, C. S., Hutchinson, D. L., & Smith, T. M. (2014). Chronology of linear enamel hypoplasia formation in the Krapina Neanderthals. *PaleoAnthropology*, 431-445.
- Guatelli-Steinberg, D. (2003). Macroscopic and microscopic analyses of linear enamel hypoplasia in Plio-Pleistocene South African hominins with respect to aspects of enamel development and morphology. *American Journal of Physical Anthropology*, 120, 309-322.
- Guatelli-Steinberg, D. (2015). Micro-to macroscopic. In: Irish, J. D., & Scott, G. R. (Eds.), *A companion to dental anthropology*, 450. Hoboken: Wiley-Blackwell.
- Hillson, S. (2005). *Teeth*. Cambridge: Cambridge University Press.
- Hillson, S. (2014). *Tooth development in human evolution and bioarchaeology*. Cambridge: Cambridge University Press.
- Hillson, S., & Bond, S. (1997). Relationship of enamel hypoplasia to the pattern of tooth crown growth: A discussion. *American Journal of Physical Anthropology*, 104, 89-103.
- Hillson, S., Grigson, C., & Bond, S. (1998). Dental defects of congenital syphilis. *American Journal of Physical Anthropology*, 107, 25-40.
- Holt, S. A., Reid, D.J., & Guatelli-Steinberg, D. (2012). Brief communication: Premolar enamel formation: Completion of figures for aging LEH defects in permanent dentition. *Dental Anthropology*, 343, 4.
- Ioannou, S., Henneberg, M., Henneberg, & R. J., Anson, T. (2015). Diagnosis of mercurial teeth in a possible case of congenital syphilis and tuberculosis in a 19th century child skeleton. *Journal of Anthropology*, 2015.
- Karnosh, L. J. (1926). Histopathology of syphilitic hypoplasia of the teeth. *Archives of Dermatology and Syphilology*, 13, 25-42.
- King, A. (1999). Diet in the Roman world: a regional inter-site comparison of the mammal bones. *Journal of Roman Archaeology*, 12, 168-202.
- Krenz-Niedbała, M., & Kozłowski, T. (2013). Comparing the chronological distribution of enamel hypoplasia in Rogowo, Poland (2nd century AD) using two methods of defect timing estimation. *International Journal of Osteoarchaeology*, 23, 410-420.
- Lambert, P. M. (2006). Infectious disease among enslaved African Americans at Eaton's Estate, Warren County, North Carolina, ca. 1830-1850. *Memórias do Instituto Oswaldo Cruz*, 101, 107-117.
- Lauc, T., Fornai, C., Premužić, Z., Vodanović, M., Weber, G. W., Mašić, B., & Šikanjić, P. R. (2015). Dental stigmata and enamel thickness in a probable case of congenital syphilis from XVI century Croatia. *Archives of Oral Biology*, 60, 1554-1564.
- Lewis, M. E. (2010). Life and death in a civitas capital:

- metabolic disease and trauma in the children from late Roman Dorchester, Dorset. *American Journal of Physical Anthropology*, 142, 405-416.
- Littleton, J., & Townsend, G. (2005). Linear enamel hypoplasia and historical change in a central Australian community. *Australian Dental Journal*, 50, 101-107.
- Lovell, N. C., & Whyte, I. (1999). Patterns of dental enamel defects at ancient Mendes, Egypt. *American Journal of Physical Anthropology*, 110, 69-80.
- Lukacs, J. R., Nelson, G. C., & Walimbe, S. R. (2001). Enamel hypoplasia and childhood stress in prehistory: new data from India and Southwest Asia. *Journal of Archaeological Science*, 28, 1159-1169.
- Lygidakis, N. A., Dimou, G., & Marinou, D. (2008). Molar-incisor-hypomineralisation (MIH). A retrospective clinical study in Greek children. II. Possible medical aetiological factors. *European Archives of Paediatric Dentistry*, 9, 207-217.
- Mardh, C. K., Bäckman, B., Holmgren, G., Hu, J. C. C., Simmer, J. P., & Forsman-Semb, K. (2002). A nonsense mutation in the enamelin gene causes local hypoplastic autosomal dominant amelogenesis imperfecta (AIH2). *Human Molecular Genetics*, 11, 1069-1074.
- Moggi-Cecchi, J., Pacciani, E., & Pinto-Cisternas, J. (1994). Enamel hypoplasia and age at weaning in 19th-century Florence, Italy. *American Journal of Physical Anthropology*, 93, 299-306.
- Ogden, A. R., Pinhasi, R., & White, W. (2007). Gross enamel hypoplasia in molars from subadults in a 16th-18th century London graveyard. *American Journal of Physical Anthropology*, 133, 957-966.
- Pitts, M., & Griffin, R. (2012). Exploring health and social well-being in late Roman Britain: an intercemetary approach. *American Journal of Archaeology*, 116, 253-276.
- Puttkonen, T. (1963). Does early treatment prevent dental changes in congenital syphilis? *Acta Dermato-Venereologica*, 43, 240.
- Radu, C., & Soficaru, A. D. (2016). Dental developmental defects in a subadult from 16th-19th centuries Bucharest, Romania. *International Journal of Paleopathology*, 15, 33-38.
- Redfern, R. C., DeWitte, S. N., Pearce, J., Hamlin, C., & Dinwiddy, K. E. (2015). Urban-rural differences in Roman Dorset, England: A bioarchaeological perspective on Roman settlements. *American Journal of Physical Anthropology*, 157, 107-120.
- Reid, D., & Dean, M. (2000). Brief communication: The timing of linear hypoplasias on human anterior teeth. *American Journal of Physical Anthropology*, 113, 135-139.
- Reid, D. J., & Dean, M. C. (2006). Variation in modern human enamel formation times. *Journal of Human Evolution*, 50, 329-346.
- Roberts, C. A., & Cox, M. (2003). *Health and disease in Britain: from prehistory to the present day*. Gloucestershire: Sutton publishing.
- Rohnbogner, A., & Lewis, M. (2016). Dental caries as a measure of diet, health, and difference in non-adults from urban and rural Roman Britain. *Dental Anthropology*, 29, 16-31.
- Sawada, J., Suzuki, T., Yoneda, M., Sato, M., Hirata, K., & Dodo, Y. (2008). Severe developmental defects of enamel in a human skeleton of the Final Jomon age from the Nakazawahama shell-mound, Iwate, Japan. *Anthropological Science*, 116, 115-121.
- Schuurs, A. (2012). *Pathology of the hard dental tissues*. Hoboken: John Wiley & Sons.
- Simmonds, A., Márquez-Grant, N., & Loe, L. (2008). *Life and death in a Roman city: Excavation of a Roman cemetery with a mass grave at 120-122 London road, Gloucester*. Oxford: Oxford Archaeological Unit Ltd.
- Skinner, M. F., Skinner, M. M., Pilbrow, V. C., & Hannibal, D. L. (2016). An enigmatic hypoplastic defect of the maxillary lateral incisor in recent and fossil orangutans from Sumatra (*Pongo abelii*) and Borneo (*Pongo pygmaeus*). *International Journal of Primatology*, 37, 548-567.
- Sundell, S., & Koch, G. (1984). Hereditary amelogenesis imperfecta. I. Epidemiology and clinical classification in a Swedish child population. *Swedish Dental Journal*, 9, 157-169.
- Van der Veen, M. (2008). Food as embodied material culture: diversity and change in plant food consumption in Roman Britain. *Journal of Roman Archaeology*, 21, 83-109.
- Walker, P. L. (2008). Sexing skulls using discriminant function analysis of visually assessed traits. *American Journal of Physical Anthropology*, 136, 39-50.
- Weerheijm, K. (2003). Molar incisor hypomineralisation (MIH). *European Journal of Paediatric Dentistry*, 4, 115-120.
- Witzel, C., Kierdorf, U., Schultz, M., & Kierdorf, H. (2008). Insights from the inside: Histological analysis of abnormal enamel microstruc-

- ture associated with hypoplastic enamel defects in human teeth. *American Journal of Physical Anthropology*, 136, 400-414.
- Wong, H. (2014). Aetiological factors for developmental defects of enamel. *Austin Journal of Anatomy*, 1.
- Wright, J. T. (1985). Analysis of a kindred with amelogenesis imperfecta. *Journal of Oral Pathology & Medicine*, 14, 366-374.
- Xing, S., Guatelli-Steinberg, D., O'Hara, M., Li, J., Wei, P., Liu, W., & Wu, X. (2016). Micro-CT Imaging and Analysis of Enamel Defects on the Early Late Pleistocene Xujiayao Juvenile. *International Journal of Osteoarchaeology*, 26, 935-946.



## Five Cases of Dental Anomalies Attributable to Congenital Syphilis from Early 20<sup>th</sup> Century American Anatomical Collections

Stella Ioannou<sup>1\*</sup>, David Hunt<sup>2</sup>, and Maciej Henneberg<sup>1</sup>

<sup>1</sup> Biological Anthropology and Comparative Anatomy Research Unit, Adelaide Medical School, The University of Adelaide, Adelaide, South Australia, 5005

<sup>2</sup> Department of Anthropology, National Museum of Natural History, Smithsonian Institution, Washington, DC, 20013-7012

**Keywords:** congenital syphilis, disrupted amelogenesis, severe hypoplasia, tooth morphology

*ABSTRACT* Specific dental abnormalities are considered pathognomonic of congenital syphilis (CS); however, European physicians recognized their variation during the late 19<sup>th</sup> to mid 20<sup>th</sup> centuries. Observations of syphilis-related dental abnormalities in American individuals from similar time periods are made to determine types of variation among the American population.

From a survey of the Smithsonian Institution's National Museum of Natural History anatomical human skeletal collection, five individuals demonstrated dental characteristics consistent with CS (P00011R, P219398, P000707, P000679, and P000161). Hutchinson's three categories of dental anomalies were used to describe variations among syphilitic individuals.

Previously identified pathological dental characteristics related to CS were present in the analyzed individuals. P00011R, 24-year-old Black female, has a maxillary right Moon's molar. P219398, approximately 20-year-old Black female, has Hutchinson's incisors and Fournier's molars. P000707, 26-year-old Black male, displays severe hypoplasia on all incisors, canines and maxillary first molars. P000679, 33-year-old Black female has "screw-driver" shaped maxillary central incisors, altered occlusal morphology of first maxillary molars and hypoplasia. P000161, 45-year-old Black female, demonstrates severe hypoplasia on incisors and canines (molars lost).

"Classic" dental characteristics of CS are not ubiquitous to all identified cases. This study exemplifies that dental anomalies associated with CS do not all have to be present for diagnosis. Although other causes for some of these anomalies are possible, observations in these five cases are most consistent with CS.

Prior to the introduction of penicillin in the 1940s, syphilis was a public health problem in the United States (Lancet, 1930; Lancet, 1937a). The prevalence of syphilis in the United States at that time is difficult to determine, as data collection for syphilis by state health departments did not begin until the early 20<sup>th</sup> Century, and the Venereal Disease Division of the U.S. Public Health Service was not created until 1918 (Nakashima et al., 1996).

To control venereal disease, various states implemented programs (free treatment, and clinics that offered free, pay, and part pay clinics) (Lancet, 1937a), and legislation (marital examination law and prenatal law) (Lancet, 1917; Prebble, 1938; Lancet, 1940; DePorte, 1941). In cases of medical intervention, mercury was used to treat congenital syphilis in the 19<sup>th</sup> and early 20<sup>th</sup> centuries throughout the United States (Conrad and McCann, 1922; Cole et al., 1929; Scheer and Fraser, 1930; Cole et al., 1933; Chargin and Saunders, 1939). Treatments of syphilis also included chemotherapies of arsenic and bismuth compounds (Lee, 1878; Cole et al.,

1929; Eller and Maloney, 1929). The chemotherapies most favored in the treatment of congenital syphilis included mercury, arsphenamine and potassium iodide (United States. Public Health Service. Division of Venereal Diseases, 1930).

The effectiveness of mercury as a treatment for syphilis has been questioned (Miller, 1858; Weatherill, 1833); although, the treatment remained popular with some physicians. In some cases, syphilitic lesions completely healed and patients became seronegative (Wakerlin, 1934). In syphilitic women treated with mercury during their pregnancy, 91.5% were efficient in completing their pregnancies successfully by live birth, while 47.6% non-treated women experienced fetal death (United States. Public Health Service. Division of Venereal Diseases, 1930). Mercury and its compounds were seen to

\*Correspondence to:

Stella Ioannou  
The University of Adelaide  
Adelaide 5005, South Australia, Australia  
email: stelzy\_25@hotmail.com

have antibacterial properties that actually reduced, or cured infections with *Treponema pallidum* (Smith, 1844; Hare, 1858; Warner, 1881; Wakerlin, 1934). Despite their possible curative effects on syphilis, mercurial treatments yield serious side effects including scarlatiniform rashes, stomatitis, pyrexia, bleeding of the rectum, and death in some cases (Chopping, 1899; French, 1909). Therefore, the use of mercury was abandoned later in the 20<sup>th</sup> century when other effective forms of treatment (i.e., penicillin) became available and mercuric treatments were dropped from clinical practice.

In paleopathology, the diagnosis of congenital syphilis (CS) is based on skeletal and dental signs. However, when skeletal signs are not present specific dental abnormalities caused by a disturbance in odontogenesis are associated with the disease (Hillson et al., 1998). Signs include Hutchinson's crescentic notched or screwdriver incisors (Hutchinson, 1859; 1887), Moon's dome-shaped molar (Moon, 1884), and Fournier's molars of "upset appearance" (Bouleversée d'aspect) (Fournier, 1886:84). These changes occur when odontogenesis is affected during the early stage of the disease. During the 19<sup>th</sup> century, Jonathan Hutchinson, was the first to note that syphilitic treatments containing mercury also affected dental development, disrupting amelogenesis. Hutchinson described that these mercury-induced dental malformations were significantly different from those caused by congenital syphilis alone, and in some cases, patients exposed to a treatment regimen involving mercury could manifest dental signs associated with the disease and treatment (Hutchinson, 1888; Moon, 1884; summarized in - Ioannou et al., 2015, 2016). It should be noted that 10-30% of patients clinically diagnosed with congenital syphilis do not manifest changes associated with disturbed odontogenesis (Švejda, 1952; Lipski and Przyłipiak, 1959). It is clear that these inconsistencies caused confusion among physicians in the past (Hutchinson, 1878) and with diagnoses in both clinical and paleopathological settings.

During late 19<sup>th</sup> and early 20<sup>th</sup> centuries, various institutions produced collections of skeletons for future research purposes. These collections included skeletons of individuals who suffered from various diseases including treponemal diseases. Today such collections provide hard evidence of the disease and its treatments, independent of government records and the literature. For some individual skeletons, there is medical documentation stating the cause of death, while others have been given differential diagnosis based on the skeletal evidence by the curator. Such diagnoses were based on paleopathological knowledge of the curator at the time.

While previous studies have focused on "typical"

dental characteristics associated with congenital syphilis, this paper will also assess the possibility of some of the dental anomalies being from the medical treatments. Therefore, the aims of this paper are: (1) to describe the variation and similarities in dental abnormalities associated with congenital syphilis in individuals either medically diagnosed with the disease or who were posthumously diagnosed by skeletal pathological conditions or dental anomalies to have been afflicted with congenital syphilis, and (2) to evaluate whether there are any indications of dental features that could be the result of treatments for congenital syphilis. Differential diagnoses of other diseases or genetic conditions that could have effects on dental characteristics are reviewed, including tuberculosis, leprosy, amelogenesis imperfecta, rickets, fluorosis, and some of the chemicals used to treat these diseases are also considered, such as mercury, arsenic, bismuth, lead and cadmium.

## MATERIALS AND METHODS

As stated above, 10-30% of patients clinically diagnosed with congenital syphilis do not manifest dental anomalies (Švejda, 1952; Lipski and Przyłipiak, 1959). To assess the range of expression of the dental anomalies attributed to congenital syphilis, those conditions as described by Jonathan Hutchinson (1859, 1863, 1878, 1887, 1888), Henry Moon (1877, 1884), Alfred Fournier (1886), and Hillson et al. (1998) are used as the criteria for the cases observed here to evaluate the likelihood of congenital syphilis in the anatomical collections and to see if comparable dental abnormalities are present. The criteria are reviewed and described by Ioannou et al. (2016).

A review of dentition in the early 20<sup>th</sup> century Robert J. Terry anatomical skeletal collection and cadaver room skeletons from the Howard University Medical School was made at the Smithsonian National Museum of Natural History (NMNH) in Washington DC. The survey focused on individuals listed as having pathological conditions related to the following: congenital syphilis, treponemal disease, lues disease, syphilis, tuberculosis, and rickets. These pathological identifications came from death certificate records, reports from the morgue records, or diagnoses made by observations of the cadavers or the skeletal elements in dissection or after skeletonization. Some of the observations made by curators were independent from the cause of death of these individuals.

Out of 38 individuals that were narrowed down from the initial survey, five individuals exhibited various dental malformations consistent with those in patients diagnosed with congenital syphilis (Excel file with data is available from SI upon request). The five individuals were P00011R, P219398, P000707,

P000679 and P000161, of which only P00011R was clinically diagnosed with congenital syphilis while living. The dentition of these individuals was analyzed to document the types and range of malformations in tooth morphology. Since human variation and their effects from disease are individualistic and often do not present the “typical” pathological manifestations of a particular disease.

To evaluate the possibility of mercury treatment of any of these subjects, portable x-ray fluorescence (pXRF) spectrometry was conducted to determine whether mercury could be detected in the enamel and bone in each of the individuals.

#### *Dental Malformation Criteria for Evaluation of Treponemal Disease*

Hutchinson (1859, 1863, 1878, 1887, 1888) recognized that dental malformations observed in children with congenital syphilis varied so considerably that he deemed it necessary to create various categories to distinguish kinds of anomalies in dental formation. His three categories of dental malformations were - syphilitic teeth, mercurial teeth, and syphilitic-mercurial teeth.

In the syphilitic category, the maxillary central incisors are the “test teeth”. The central incisors can appear “peg like” or screwdriver in shape, are dwarfed and display a crescentic notch on the incisal edge (Hutchinson’s incisors). Some of these features can also be observed in the maxillary lateral incisors and mandibular incisors (Hutchinson, 1887; Hillson et al., 1998). Other characteristics within the syphilitic category include malformations observed in the first permanent molars (Hutchinson, 1887) labeled as Moon’s molar and Fournier’s molars. Moon’s molar is “smaller than usual and dome-shaped” (Moon, 1877), while Fournier’s molars either have several nodules and tubercles or have a flat surface (Fournier, 1886). Both varieties of Fournier’s molars have a clear demarcation between healthy and diseased enamel.

Mercurial teeth demonstrate severe enamel hypoplasia, caused by treatments containing mercury. The first permanent molars are the “test teeth”. The enamel is deficient and appears rugged, pitted, and dirty with a honeycomb appearance (Hutchinson, 1878; Ioannou et al., 2016). Dentine is affected in severe cases with the appearance of multiple spines or tubercles. The entire occlusal surface or a central area can be affected. Incisors and canines are also affected with severe linear enamel hypoplasia that crosses these anterior teeth at the same level. The enamel between the linear enamel hypoplasia and the tip of the crown is deficient (Hutchinson, 1878), and pitting hypoplasia is also common. Premolars in most cases appear normal. However, the characteristic notch

observed in syphilitic incisors is not mimicked in mercurial conditions only (Hutchinson, 1878). Syphilitic-mercurial teeth demonstrate a combination of both syphilitic and mercurial dental malformations (Hutchinson, 1878; Moon, 1884; Ioannou et al., 2016). The upper central incisors can have a peg-like or screw-driver shape (outline), the incisal edges appear characteristically notched, and any part of the enamel surface can be hypoplastic, pitted and discolored. The first permanent molars can show an absence of enamel on the occlusal surface of the crown but have healthy enamel on its sides (Hutchinson, 1878).

## RESULTS

*Terry Collection P00011R* (Fig. 1) is an African American female, born in 1918 and died in 1942, at 24 years old. The primary cause of death was attributed to lobar pneumonia, but was clinically diagnosed with congenital syphilis in 1930 and was subsequently institutionalized until her death, 11 years and 2 months later. This is the only individual that was diagnosed with congenital syphilis during the life of the individual.

All maxillary incisors and left maxillary canine were lost many years before death (Fig. 1A). The first right upper molar has a clearly narrowed occlusal surface with pitting hypoplasia resembling a dome shape (Moon’s molar) (Fig. 1B & 1C). The left first upper molar has a narrowed occlusal surface, and is largely destroyed by dental caries. All the premolars and right canine have normal morphology. The second and third permanent molars have normal molar morphology. The left third molar has a single carious lesion on the disto-buccal aspect. Upper alveolar process shows periodontal changes on both sides.

The mandibular teeth present include the left and right lateral incisors, left canine, left and right first premolars, left second premolar and left and right second and third permanent molars. The lateral incisors appear peg like in shape (Fig. 1D & 1E). Both first permanent molars were lost many years before death, and the alveoli are completely healed (Fig. 1F). The occlusal surface of the left second premolar and second and third permanent molars are destroyed by caries. Bone resorption suggests periodontal disease (Fig. 1D & 1F). Cranial morphology is normal, no ‘saddle nose’ is present, and the nasal cavity and palate are normal. The molars in P00011R are syphilitic.

*Howard Collection P219398* (Fig. 2) is an African American female who died in 1903 in Washington, DC with no recorded cause of death and was autopsied at Howard University School of Medicine. There is not a reported age at death, but dental and skeletal development indicators suggest this individual died between 20 and 25 years of age. Previous evaluation

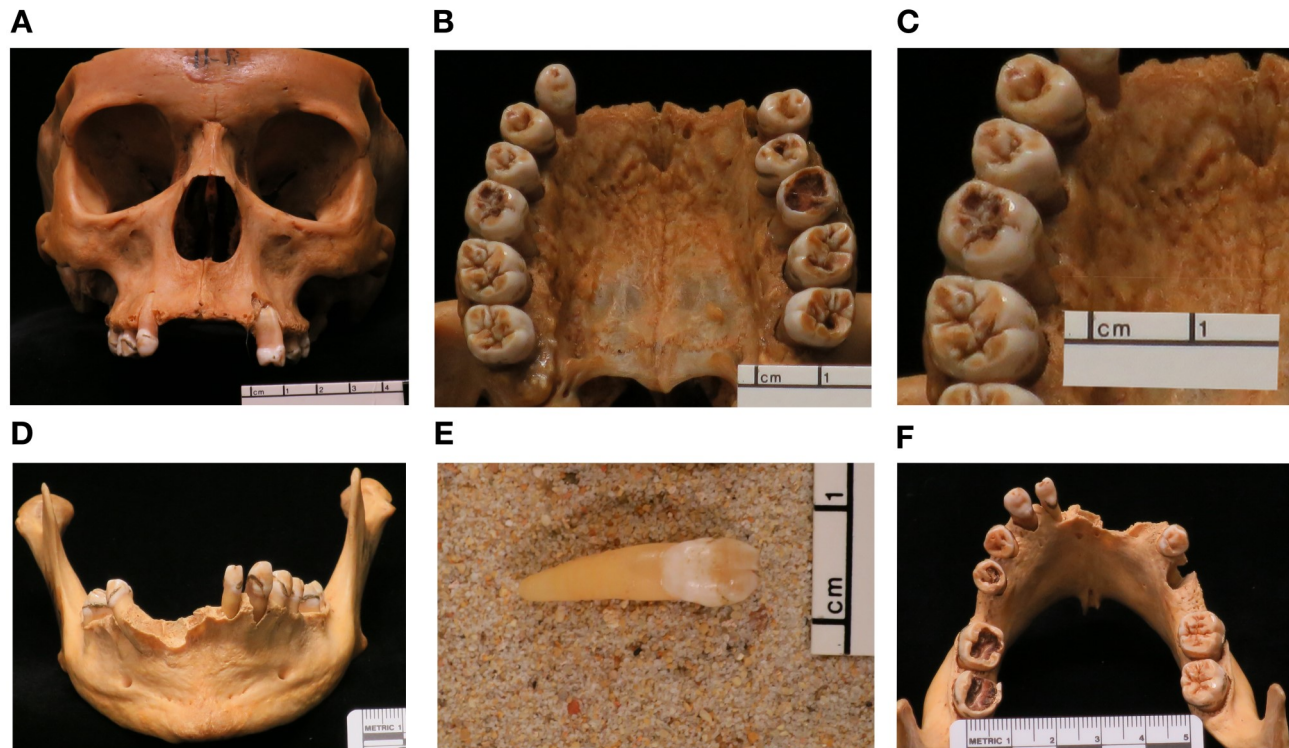


Figure 1. Individual P00011R, 24yrs old female. (A) Anterior view of maxilla: Central and lateral incisors, and left canine missing. No saddle nose. (B) Occlusal view: Most teeth have normal morphology. Carious destruction of the left first molar does not allow precise observation, but it seems that the crown has a narrow occlusal surface. (C) First right permanent molar has a narrow and reduced occlusal surface resembling Moon's molar. Pitting is also present. (D) Anterior view of the mandible. Periodontal disease is evident. (E) Loose anterior tooth of mandible; lateral right incisor. (F) Occlusal view of mandible: No first molars, most likely lost to caries.

by researchers and curators identified the dental anomalies and considered them to be the product of congenital syphilis and this was noted in the Smithsonian pathology files. All maxillary teeth are present, except the left second and third permanent molars. The maxillary central incisors are marked by rounded mesial and distal incisal edges. The labial aspects of the incisal one-third of both crowns have centrally located hypoplastic defects. On the right central incisor, this hypoplasia resulted in a smooth crescentic pit, while on the left central incisor there is irregular hypoplastic pitting in the same location (Fig. 2A). Multiple short lines of hypoplastic enamel are also apparent on the lingual surface of both teeth. The mesial and distal edges of the right and left lateral incisors are also rounded off, giving both teeth a peg-like shared crown. Multiple pits are present on the lingual surface of both lateral incisors. The tips and lingual aspects of the canines display hypoplastic pitting. The occlusal surfaces of the first permanent molars have diminished areas compared to the dimensions of the rest of the crown (Fig. 2B & 2C). There are also scattered hypoplastic pits and various

areas of the occlusal surfaces have irregular grooves (Fig. 2C). The molars resemble both types of Fournier's molars. The second right permanent molar has normal molar morphology. The left second molar was lost during life, as the alveolar bone has healed.

The mandibular dentition is nearly complete. The left canine was lost post-mortem, while the alveolus of the lower left third molar is healed. The central incisors are affected by severe enamel hypoplasia and exposed dentine on the incisal one-fourth of the crown (Fig. 2D). The morphology and enamel of all other teeth, except the first permanent molars, appears normal. The occlusal surfaces of the crowns of the first permanent molars are reduced in size and severely hypoplastic (Fig. 2E & 2F). The cusps appear to be reduced in size and multiple tubercles are visible (Fig. 2F). This appears similar to Fournier's nodule-type molar. The dentine is also exposed in places. The morphology of the second permanent molars appears normal, with the left demonstrating signs of crenulation. The entire crown of the third right permanent molar is missing with only the root present while the left was lost during life as indicated by

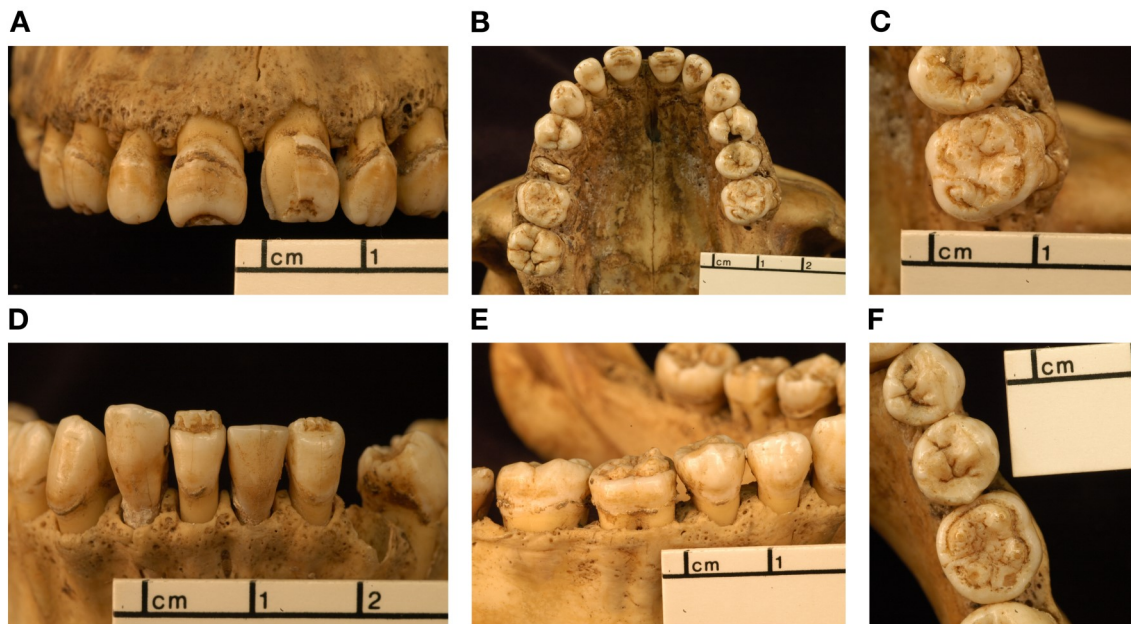


Figure 2. P219398, 20yrs old female. (A) Anterior view of maxilla: Labial aspect of permanent central incisors. Right incisor has thin enamel along incisal edge forming a crescentic pit. Irregular pitting is noted in the same location on the left incisor. Lateral incisors are peg-like in shape. (B) Occlusal view of maxilla: Occlusal surfaces of the first permanent molars are reduced and demonstrate scattered hypoplastic pits and irregular grooves. (C) Occlusal view of the left first permanent molar of maxilla demonstrates pitting and grooves in enamel. The occlusal surface is also reduced. (D) Anterior view of mandible: Central incisors demonstrate enamel hypoplasia and exposed dentine on the 1/4 of the crown. Note, the central and lateral incisors appear to be incorrectly inserted into mandible post mortem. (E) Lateral view of right side of mandible: First permanent molar resembles that in the maxilla. (F) Occlusal view of right mandibular first permanent molar: it has reduced surface, multiple tubercles and pitting hypoplasia.

healed alveolar bone. The morphology of the alveolar bone suggests some periosteal inflammation was present at the time of death. The dental abnormalities in P219398 are most consistent with syphilitic malformations.

*Terry Collection P000707* (Fig. 3) is an African American male, aged 26 years at the time of his death in 1929 in St. Louis, Missouri from pulmonary tuberculosis. Previous evaluation by researchers and curators identified the dental anomalies and considered them to be the product of congenital syphilis and this was noted in the Smithsonian pathology files. All permanent teeth, including the third molars, are present. The central incisors are marked by minor notches and isolated pits along the incisal edges. Enamel adjacent to the incisal edge appears healthy with minor pitting, however, the middle third of the crown shows progressively more severe pitting hypoplasia that ends with extremely deep defects that likely penetrate the pulp cavity (Fig. 3A). The cervical portion of the crowns appears normal. The left lateral incisor is affected by a similar progressively pitted enamel defect on the incisal third of the crown (Fig. 3A). The incisal third of the right lateral incisor has been lost at a point where the pitting morphology appears like that observed in its left-side antimer. A similar

enamel defect affects the left canine (Fig. 3B). The enamel of the right canine appears to have broken off postmortem. The lingual surfaces of these anterior maxillary teeth are affected by irregular hypoplastic defects, demonstrating a mottled like appearance. The premolars have normal morphology. The occlusal two thirds of the crown of the first permanent molars are hypoplastic, with pitting hypoplasia and reduced surfaces in comparison to the other permanent molars present (Fig. 3C). However, some normal groove patterns of the occlusal surfaces are preserved. Minor pitting is present on the second and third permanent molars. The second left and third right permanent molars demonstrate crenulation. The alveolar bone suggests some periosteal inflammation was present.

The mandibular dentition consists of all permanent teeth, except the left and right first molars. Two thirds of all incisors and canines are affected by severe hypoplastic defects (Fig. 3D). The left and right first molars were lost antemortem. The alveoli for the first molars are healed but not completely resorbed (Fig. 3E). The second permanent molars and the left third permanent molars have normal molar morphology but demonstrate crenulation (Fig. 3F). The third left molar appears larger than the second permanent molars. A supernumerary fourth molar is present on

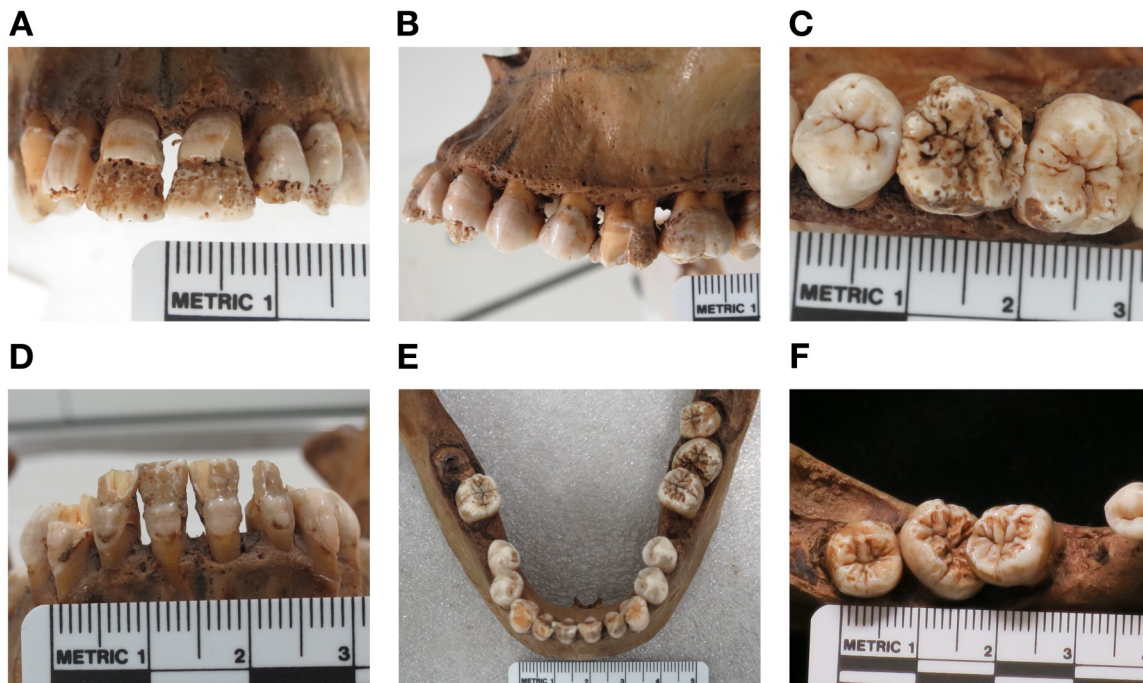


Figure 3. P000707, 26yrs old male. (A) Anterior view of maxilla: Incisal edges of the maxillary central incisors appear healthy with isolated pits. The middle third of the crown demonstrates progressively severe enamel hypoplasia. Similar enamel hypoplasia is evident on the lateral incisors and canines. (B) Lateral view of the left side of maxilla: The lateral incisor and canine display enamel defects similar to the central incisors. (C) Occlusal view of upper right first permanent molar, note unusual configuration of enamel on the occlusal surface. Two thirds of the occlusal surfaces of the first permanent molars are severely hypoplastic, although some normal groove patterns are preserved. (D) Anterior view of the mandible: Two thirds of all incisor and canines crowns are affected by severe hypoplastic defects. (e) Occlusal view of mandible, note both first molars are missing. (F) Close up of supernumerary fourth molar. Note crenulation on occlusal surfaces of other molars.

the left side (Ioannou & Henneberg, 2016). It is smaller in size in comparison to the other molars and has normal molar morphology (Fig. 3F). P000707 demonstrates dental signs that are suggestive of mercuric treatments.

*Terry Collection P000679* (Fig. 4) is an African American female, who died of tuberculosis at 33 years of age in St. Louis, Missouri in 1928. Previous evaluation by researchers and curators identified the dental anomalies and considered them to be the product of congenital syphilis and this was noted in the Smithsonian pathology files. The maxillary dentition is complete, except for the left third molar. It is unclear whether the absence of this tooth was due to agenesis or antemortem tooth loss. The maxillary central incisors have narrowed incisal edges with rounded corners. Located at the midcrown on the labial surface are hypoplastic defects that consist of an approximately oval-shaped area of thinner enamel, which is surrounded by pitting that extends distally to the one-third of the crown from the incisal edge (Fig. 4A). Shoveling is apparent on the lingual aspects, as is one linear hypoplastic line on the cervical third of the crowns (Fig. 4B). The lateral incisors appear peg like

in shape with round mesial and distal edges. A couple of isolated pits are evident on the right lateral incisor. One hypoplastic line runs at the same level on both lateral incisors on the labial aspect. The left canine has isolated pits on the tip of the crown. Pits and grooves are present on the lingual aspect of the canines. Pitting is on the occlusal surface and lingual aspect of the first premolars. The right second premolar has a deep groove on the lingual surface. Maxillary first molars have occlusal surfaces that are reduced in size and have abnormal enamel formation (Fig. 4C). There is a demarcation between diseased and healthy enamel by pitting hypoplasia (Fig. 4D). The second molars and third right molar have normal morphology.

The mandibular dentition is represented by a full set of anterior teeth from the left first premolar to the right first premolar. The right third molar and the left second molar are present. All other posterior teeth were lost antemortem as indicated by complete alveolar remodeling (Fig. 4E). The incisors are marked by multiple notches on their incisal edges. Shallow indistinct furrows are present about one-third the length of the crown (Fig. 4F). Isolated pits are present on the lateral incisors. Part of the enamel on the labial

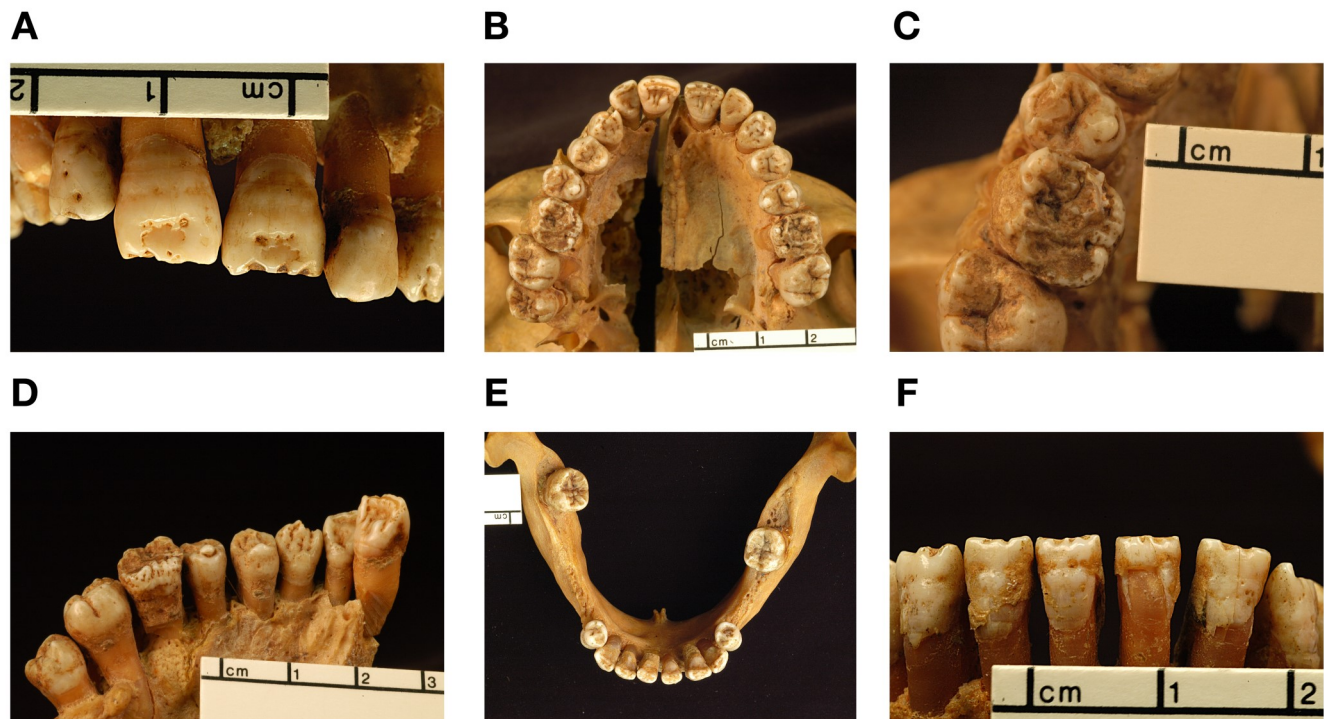


Figure 4. P000679, 33yrs old female. (A) Hypoplastic defects on labial surface of central incisors. Those that are in the incisal third of the crown are large and oval in shape and are centrally located with small-scattered pits. Some other teeth also display pitting. (B) Occlusal view of maxilla: occlusal surfaces of first permanent molars have abnormal formation of the enamel. (C) Close up of upper right first molar. (D) Palatine view of the right maxillary dentition: Note demarcation between diseased and healthy enamel in the first permanent molar. (E) Occlusal view of mandible. (F) Anterior view of mandible: Incisors are marked by multiple notches on their incisal edges while shallow indistinct furrows are present about one-third the height of the crown.

surface of the left central incisor has broken off post-mortem. The first premolars have isolated pits on their surfaces. All other remaining mandibular teeth have normal morphology. The dental defects in P000679 are comparable to Hutchinson's dental observations for CS and suggestive of mercurial teeth morphology.

*Terry Collection P000161* (Fig. 5) is an African American female who was approximately 45 years of age at the time of death and added to the skeletal collection in 1925. No cause of death is recorded in the morgue records. Previous evaluation by researchers and curators identified the dental anomalies and considered them to be the product of congenital syphilis and this was noted in the Smithsonian pathology files. All maxillary teeth are present, except the right second premolar and the left first molar. The incisal margins of the central and lateral incisors are notched. The labial surfaces of crowns of anterior teeth have malformed enamel, featuring irregular pitting and a deep furrow located about one-third of the crown height proximal to the incisal edge (Fig. 5A). A second furrow appears on the left central incisor on the cervical third of the crown. The furrows of the anterior teeth appear approximately at the same level. Some enamel was lost postmortem on the cervical

third of the right central incisor and parts of the mesial aspect of the left central incisor. Numerous dark colored pits run horizontally along the middle third of the crown of the central incisors and the incisal third of the lateral incisors and tip of canines. (Fig. 5A). Similar pitting and linear hypoplastic defects occur on the lingual surfaces of these teeth (Fig. 5B). The morphology of the premolars and other molars still present appears normal. A fragment of the occlusal surface of the right first permanent molar is marked by irregular enamel and pitting. A large carious lesion is present in the disto-lingual area of the right first permanent molar, while an interproximal carious lesion is evident towards the mesio-lingual end of the crown. The left first molar has been lost most likely due to dental caries. The alveolar bone has not healed completely, so it is possible the loss occurred shortly before death. The morphology of both second molars and third molars appears normal. On the palate anteriorly on the right side there is a circular bony depression surrounded by elevated bone. There is a large perforation on the right side of the palate. There is also some pitting in the palate that is more apparent near the right first permanent molar.

The mandibular dentition consists of the left and right lateral incisors, canines, first and second premo-

lars, second molars and the left third molar. The central incisors were lost post mortem, while both first molars and the right third molar were lost ante-mortem. The alveoli for both first molars are completely remodeled, but the alveolus for the left has been less remodeled than the right. The third right molar alveolus is healed. Similar to the maxillary dentition, severe linear and pitted enamel hypoplastic defects are present on the lateral incisors and canines (Fig. 5C). The multiple hypoplastic lines run along at the same level of the crown of these teeth on both labial and lingual surfaces (Fig. 5C & 5D). The tops of the crowns of the first premolars appear hypoplastic. Pitting and two small carious lesions are present on the occlusal surface of the left first premolar. The crowns of both second premolars appear normal. The abnormalities seen in the dentition of P000161 are consistent with Hutchinson's description of patients with CS and possibly some features suggestive of mercury effects.

#### *Mercury testing using pXRF*

An exploratory, qualitative analysis using a portable x-ray fluorescence analyser (pXRF) was performed to

see if any of the individuals above might have mercury or other chemical elements possibly related to treatment for CS and the cause of the dental abnormalities. The analysis was conducted using a Bruker Tracer III-V handheld analyser on portions of hypoplastic enamel on the central and lateral incisors for all of the individuals, except individual P00011R, which lacked central incisors - instead, a lateral incisor and canine were tested. The analysis was conducted with settings optimized for mercury (0.001" Cu, 0.001" Ti, 0.012" Al filter at 40 keV/16 micro amps for 300 seconds, without vacuum). Bone testing was done on the femur of the same individuals to test for contamination if high readings of any particular elements were found. No mercury was detected. The lack of mercury in these individuals most likely can be attributed to amounts of mercury that may be too minute for the instrument's detection capabilities (see Zuckerman, 2016:50 for discussion on mercury detection with pXRF).

#### *Differential Diagnosis*

Diseases that interfere with odontogenesis and amelogenesis are considered for a differential diagnosis.

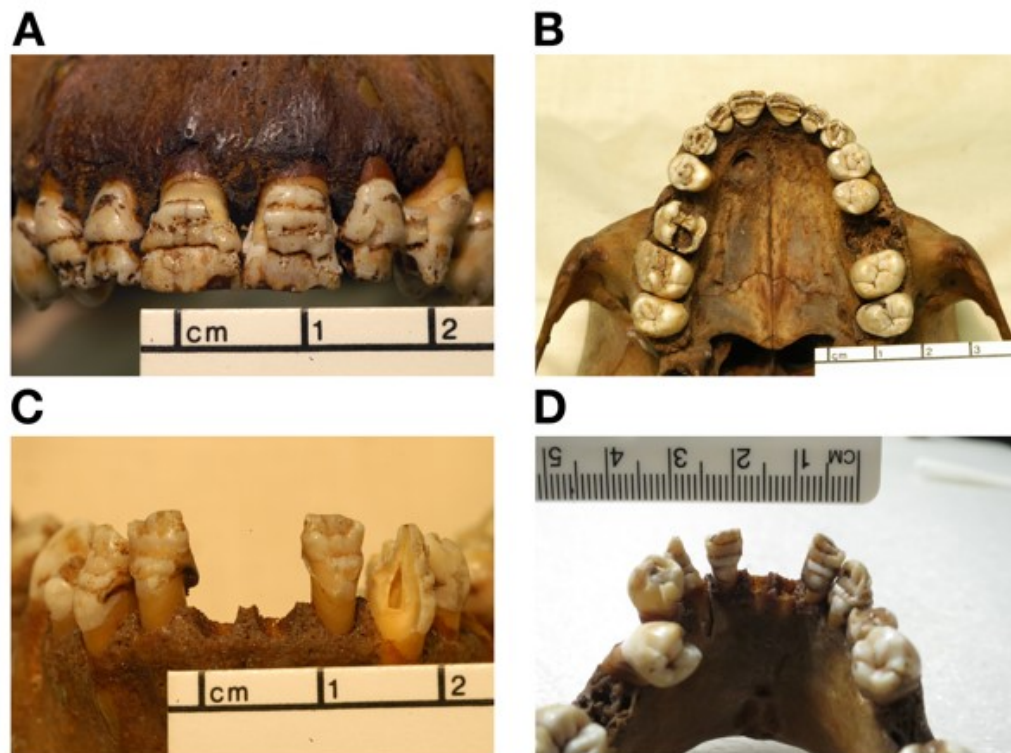


Figure 5. P000161, 45yrs old female. (A) Severe hypoplastic enamel of the maxillary incisors and canines. Incisal thirds of the central and lateral incisors' and canines' crowns are hypoplastic with deep furrows. Dark colored pits run horizontally across the crowns. (B) Occlusal view of maxilla: Linear and pitting hypoplasia noted on the lingual surface of anterior teeth. (C) Anterior view of mandible: Severe linear and pitted enamel hypoplasia on the lateral incisors and canines. (D) Lingual view of mandible: Pitted and linear enamel hypoplasia evident on lateral incisors and canines corresponds to that on labial surface.



These include tuberculosis, leprosy, amelogenesis imperfecta, rickets and fluorosis, as well as elements that have been used as treatments or are known to affect tooth development such as mercury, arsenic, lead, bismuth, and cadmium.

Tuberculosis is a chronic disease that predominately affects the ribs, vertebrae, and the large joints of the body. In adult onset of tuberculosis, there would be no effect on the dentition. In cases of childhood tuberculosis, the most common dental abnormalities are associated with developmental stress - linear enamel hypoplasia (Dabernat and Crubézy, 2010; Bedić et al., 2015); carious lesions (Formicola et al., 1987; Hlavenková et al., 2015); and decreased enamel thickness (Formicola et al., 1987). Since dental signs observed in childhood tuberculosis do not resemble the dental abnormalities or the severity observed in the five cases, tuberculosis is not likely and would be ruled out as a differential diagnosis.

Leprosy is a chronic disease that affects the skin and peripheral nervous system with skeletal loss by resorption in the latter stages of the disease. It is a slow and progressive disease, signs of the disease can start to develop from six months to 30 years (World Health Organization, 2012). Dental abnormalities that have been reported in skeletal cases with evidence of leprosy include linear enamel hypoplasia (Boldsen, 2005) (which might be correlated to possible frailty in the individuals, rather than leprosy itself), and constriction of the roots of the upper permanent central incisors (leprogenic odontodysplasia) (Roffey and Tucker, 2012) that might be related to the resorption of the alveolus rather than development effects of dental formation (Roberts 2011). These observations are not common or diagnostic of the disease. If a child were to be infected with leprosy, since its macroscopic expression would be long-term, it is assumed that the disease would not severely affect dental development, possibly only producing linear enamel hypoplasias from insults to development. It is unlikely that there would be the severity of dental pathology similar to those in the described cases here. Since leprosy is predominately an adult disease, if in children it would not have the severe effects as seen in CS, therefore, leprosy is ruled out as a differential diagnosis.

Amelogenesis imperfecta (AI) is a hereditary condition characterized by enamel defects. Phenotypic expression of the condition is caused by a disturbance in ameloblasts secretions producing hypoplasia, hypocalcification, hypomaturation and hypomaturation-hypoplasia with taurodontism (Gadhia et al., 2012; Prasad et al., 2016). Amelogenesis imperfecta also manifests in enamel discoloration, enamel pitting, and thin enamel (Kar et al., 2012; Gerdolle et al., 2015; Rogers et al., 2016). The prevalence of AI varies

between populations from 43:10,000 in Turkey to 1.25:10,000 in Israel (Gadhia et al., 2012). Amelogenesis imperfecta is an unlikely differential diagnosis for the described cases since AI tends to affect amelogenesis in most all or all teeth – this is unlike congenital syphilis where only specific teeth are affected.

Rickets is a disorder caused by either a lack of vitamin D or phosphorus. These metabolic deficiencies affect tooth mineralization and bone development. Rickets may cause some non-severe linear or pitting-type enamel hypoplasia and in cases discoloration and enamel opacities (Zambrano et al., 2003; Davit-Beal et al., 2014). Like AI, rickets more uniformly affects the teeth. Therefore, with the severity of hypoplastic defects described and the specific tooth involvement, this is not consistent with rickets and their differential diagnosis can be ruled out.

Consumption of large amounts of fluoride can lead to fluorosis, and specifically in developing dentition will cause disturbance of amelogenesis. Enamel will appear discolored (yellow to dark brown), demonstrate white opaque patches or lines, or pitted or mottled hypoplasia (Sherwood, 2010; Muñoz et al., 2013). Similar to AI and rickets, fluorosis does not affect selected teeth, and its hypoplastic effects are less severe than those described in the five cases presented here. Thus, the diagnosis of fluorosis is unlikely.

Mercury was used for medicinal purposes throughout the United States to treat syphilis and congenital syphilis (Cole et al., 1929; United States. Public Health Service. Division of Venereal Diseases, 1930). Mercury was administered in various forms but was most commonly injected intramuscularly or rubbed onto the skin. Treatments containing mercury ranged from one and a half to fourteen grams of solution or ointment (Cole et al., 1929; Cole 1933). Since some of the malformations observed in P000707, P000679 and P000161 could be suggestive of the mercurial or syphilitic-mercuric category set by Hutchinson (1878) and Moon (1884), it is possible that mercury might have caused the dental malformations. There is no proof that any of these individuals may have had treatments and the one clinically diagnosed case (P00011R), was diagnosed at an age that would have excluded the severe effects of dental malformation if mercury were administered after her diagnosis.

Arsenic was also used to treat syphilis/congenital syphilis; however, its effects on enamel development in children with congenital syphilis are limited. Arsenical poisoning has been found to cause tooth sensitivity and tooth abrasion in children (Sunny, 2013), but nothing in the way of severity of the anomalies caused by mercury. Thus, the possibility of arsenic poisoning or treatment is an unlikely differential di-

agnosis.

Bismuth was introduced later than mercury and arsenic, and was used in conjunction with these to treat syphilis and congenital syphilis. Bismuth was noted to cause pigmentation of gums and the enamel, most frequently seen on the labial surfaces of the lower and upper central incisors and in prolonged acute cases, loosening of the teeth (McCarthy and Dexter 1935; Dean, 1943). The common factor observed in bismuth poisoning is that the cervical portion of the incisors was the most constant location for pigmentation (McCarthy and Dexter 1935; Dean, 1943). We see none of this pigmentation, and these individuals would have been too young to have received bismuth treatments, thus, excluding this as a differential diagnosis.

Lead was considered a possible cause in dental development, but previous studies have not found lead to cause enamel abnormalities. High levels of lead only result in a decrease in microhardness of enamel (Gerlach et al., 2002; Youravong et al., 2005) coupled with increases in abrasion and discoloration (Gil et al., 1996). Normal enamel morphology has been observed in cases where high levels of lead were present (Gerlach et al., 2002; Youravong et al., 2005).

Cadmium, although not used to treat syphilis or congenital syphilis, is known to accumulate in enamel; however, its effects on enamel development are limited in the literature. Wilson and Deeds (1939) noted that cadmium toxicity caused bleached white enamel discoloration. Since that is not observed in the discussed individuals, cadmium is unlikely diagnosis.

## DISCUSSION AND CONCLUSIONS

Syphilis was a disease that caused serious problems in the United States during the late 19<sup>th</sup> and early 20<sup>th</sup> centuries, with various measures taken to control its spread (Lancet, 1930; Lancet, 1937a; Lancet, 1917; Prebble, 1938; Deporte, 1941). While various programs and legislations were initiated, treatments (including mercury) were of primary importance to reduce prevalence rates (Lancet, 1921; Lancet, 1937a; Lancet, 1939). Even though mercury was known to produce side effects, similarly to other chemotherapies (arsenic and bismuth), it was still considered the most effective, being used on its own or in combination with other pharmaceuticals (Lancet, 1937b). However, the healing nature of mercury has also been called into question due to non-systematic recording of treatments and outcomes in the 19<sup>th</sup> century, as well as misdiagnosis of the decades-long quiescence of the disease as “cured” (Zuckerman, 2016).

Individual P00011R was diagnosed in life with congenital syphilis. The only detectable manifestations of this diagnosed condition are visible in her teeth. While some of her teeth are missing, those that

are present, especially the first permanent molars, are highly consistent with the anomalous condition found in cases of congenital syphilis. The dome-shaped and reduced occlusal surface of her first permanent molars is obviously a consequence of developmental disruption caused by congenital syphilis. They resemble those described by Moon (1884), but due to developmental variability, are not identical to the description.

While congenital syphilis was diagnosed and recorded only in this one individual, the other four individuals display dental changes that fit the broad range of changes described by Hutchinson (1859, 1863, 1878, 1887, 1888), and Moon (1877, 1884). Individual P219398 demonstrates tooth morphology that fits the syphilitic category described Hutchinson. The right central incisor displays a crescentic groove towards the incisal edge. Hutchinson (1863) describes that once this thin enamel has broken off, the characteristic notch is present.

The hypoplastic lesions in the dentition of individuals P000707 and P000161 are of significant severity. In P000707, enamel malformations in the maxillary central incisors begin approximately 2mm from the incisal edge and a normal groove pattern is visible on the very occlusal surface of the first permanent molars, indicating malformation in amelogenesis in the first months of the infant’s life. The lateral incisors and canines demonstrate similar enamel defects but are located at different crown heights that correspond to the differences in the timing of formation of these teeth. Crown development of first permanent molars begins perinatally, permanent central incisors begin to form at approximately 3-4 months of age, lateral incisors at approximately 10-12 months and canines at six months (Nelson & Ash, 2010). The crown of first molars is completed at about 2.5-3 years of age, both incisors at approximately 4-5 years of age, and at about 6-7 years of age for canines (Nelson & Ash, 2010). Judging from the position of hypoplastic defects (reflecting the mercurial category features by Hutchinson) these changes would occur at about 2.0-2.5 years of age.

The pathological changes in the dentition of individual P000161 follow similar interpretation for development and hypoplastic events similarly to individual P000707. However, hypoplastic defects are positioned somewhat earlier in the individual’s life and ceased later than in individual P000707. The severe enamel abnormalities observed in individual P000161 are changes that are more similar to the examples of the mercurial category as described by Hutchinson. But as presented above, no record of this treatment can be attributed to this individual.

Individual P000679 has enamel defects of the maxillary central incisors that are much like the mercurial

category described by Hutchinson. Whatever disturbances caused the anomalous formations of the teeth would have to have started not long after birth or from treatment to the mother - the abnormal enamel occurs much closer to the incisal margin than that seen in either individual P000707 or P000161. But again, there is no record of this treatment attributable to this individual.

In skeletal collections when medical information is not available, paleopathologists make differential diagnoses from the skeletal/dental evidence using the knowledge available at that time. During the turn of the last century and into the 20<sup>th</sup> century R. Terry, D.S. Lamb, A. Hrdlicka, T.D. Stewart and J.L. Angel made diagnoses of pathological conditions and anomalies on the anatomical and archaeological remains using their familiarity with the pathological understanding from their medical experience, and their knowledge of medical treatment for various diseases. For the individuals studied here, notations of the dental and skeletal observations related to or attributable to "treponemal disease" were made in the Smithsonian records from these scientists based on their observations and knowledge of the disease. In these records, differential diagnoses were often not listed, and thus in some cases, the labeling of a disease may have been from the observations, not from the clinical record of cause of death. From what has been observed in this study, these individuals encompass a range of variation in the dental abnormalities that have occurred in syphilitic patients. The findings of this study provide examples of this range of manifestations, discussing the basis for the malformations, and provide additional insight into identifying CS in future studies.

#### ACKNOWLEDGMENTS

The authors would like to thank Dr. Rhonda Coolidge for her analysis and report using the pXRF. The instrument was made available by the Smithsonian Anthropology Repatriation Osteology Laboratory. We also acknowledge the monumental effort of Martin Coolidge in acquiring the Death Certificates for the majority of the Terry Collection individuals - which allowed for determination of diagnosed congenital syphilis in P00011R. The first author would like to acknowledge the Australian Government Research Training Program Scholarship.

#### LITERATURE CITED

- Bedić, Ž., Vyroubal, V., Tkalčec, T., Šlaus, M. (2015). A case of childhood tuberculosis from modern period burial from Crkvari, Northern Croatia. *Podravina: Journal for Multidisciplinary Research*, 14, 64-72.
- Boldsen, J. L. (2005). Leprosy and Mortality in the Medieval Danish Village of Tirup. *American Journal of Physical Anthropology*, 126, 159-168.
- Chargin, L., Saunders H. C. (1939). New York Academy of Medicine, section of dermatology and syphilis. *Archives of Dermatology and Syphilology*, 39, 175-189.
- Chopping, A. (1899). Notes of 84 cases of syphilis treated by the intravenous injection of cyanide of mercury. *Lancet*, 153, 432-437.
- Cole, H.N., Gammel, J., Schreiber, N.E., Sollmann, T. (1929). Mercuric salicylate: A study of its excretion in the treatment of syphilis. *Archives of Dermatology and Syphilology*, 19, 125-130.
- Cole, H. N., De Wolf, H. F., Schreiber, N. E., Sollmann, T., Van Cleve, J. (1933). Mercurial inunctions in the treatment of syphilis: Excretion of mercury following the use of mild mercurous chloride inunctions; mode of absorption of mercury from skin. *Archives of Dermatology and Syphilology*, 27, 1-11.
- Conrad, A. H., McCann, C. H. (1922). XXVI. Results in the treatment of Wassermann-fast syphilis by intravenous mercuric chlorid. *Archives of Dermatology and Syphilology*, 6, 50-54.
- Dabernat, H., Crubézy, E. (2010). Multiple bone tuberculosis in a Child from Predynastic Upper Egypt (3200 BC). *International Journal of Osteoarchaeology*, 20, 719-730.
- Davit-Béal, T., Gabay, J., Antonioli, P., Masle-Farquhar, J., Wolikow, M. (2014). Dental complications of rickets in early childhood: case report on 2 young girls (Case study). *Pediatrics*, 133, e1077-1081.
- Dean, M.R. (1943). Oral Manifestations of Bismuth Therapy in the Treatment of Syphilis. *The Journal of the American Dental Association*, 30, 651 - 657.
- Deporte, J.V. (1941). Premarital and prenatal tests for syphilis. *Lancet*, 238, 59.
- Eller, J.J., Maloney, E.R. (1929). New York Academy of Medicine, section on dermatology and syphilis. *Archives of Dermatology and Syphilology*, 19, 125-130.
- Formicola, V., Milanese, Q., Scarsini, C. (1987). Evidence of spinal tuberculosis at the beginning of the fourth millennium BC from Arene Candide Cave (Liguria, Italy). *American Journal of Physical Anthropology*, 72, 1-6.
- Fournier, A. (1886). *La syphilis héréditaire tardive*. Paris: G. Masson.
- French, H.C. (1909). The treatment of syphilis by intramuscular injection of insoluble salts of mercury as contrasted with the inunction method: A critical rejoinder. *Lancet*, 174, 920-924.
- Gadhia, K., McDonald, S., Arkutu, N., Malik, K. (2012). Amelogenesis imperfecta: an introduction. *British Dental Journal*, 212, 377-379.
- Gerdolle, D., Mortier, E., Richard, A., Vailati, F.

- (2015). Full-mouth adhesive rehabilitation in a case of amelogenesis imperfecta: a 5-year follow-up case report. *International Journal of Esthetic Dentistry*, 10, 12-31.
- Gerlach, R.F., Cury, J.A., Krug, F.J., Line, S.R.P. (2002). Effect of lead on dental enamel formation. *Toxicology*, 175, 27-34.
- Gil, F., Facio, A., Villanueva, E., Pérez, M.L., Tojo, R., Gil, A. (1996). The association of tooth lead content with dental health factors. *Science of the Total Environment*, 192, 183-191.
- Hare. (1858). University College Hospital: Congenital syphilis in an infant a few weeks old. *Lancet*, 72, 172-172.
- Hillson, S., Grigson, C., Bond, S. (1998). Dental defects of congenital syphilis. *American Journal of Physical Anthropology*, 107, 25-40.
- Hlavenková, L., Teasdale, M. D., Gábor, O., Nagy, G., Beňuš, R., Marcsik, A., Pinhasi, R., Hajduh, T. (2015). Childhood Bone tuberculosis from Roman Pecs, Hungary. *HOMO - Journal of Comparative Human Biology*, 66, 27-37.
- Hutchinson, J. (1859). *Transaction of the Pathological Society of London. Including the report of the proceedings for the session 1858-9*. London: J.W Roche.
- Hutchinson, J. (1863). *A clinical memoir on certain diseases of the eye and ear, consequent of inherited syphilis: with an appended chapter of commentaries on the transmission of syphilis from parent to offspring, and its more remote consequences*. London: John Churchill.
- Hutchinson, J. (1878). *Illustrations of clinical surgery consisting of plates, photographs, woodcuts, diagrams etc. Illustrating surgical diseases, symptoms and accidents, also operative and other methods of treatment, with descriptive letterpress*. London: J. & A. Churchill.
- Hutchinson, J. (1887). *Syphilis*. London: Cassell & Company, Limited.
- Hutchinson, J. (1888). *Illustrations of clinical surgery consisting of plates, photographs, woodcuts, diagrams etc: illustration surgical diseases, symptoms and accidents, also operative and other methods of treatment, with descriptive letterpress*. London: J. & A. Churchill.
- Ioannou, S., Henneberg, M., Henneberg, R.J., Anson, T. (2015). Diagnosis of Mercurial Teeth in a Possible Case of Congenital Syphilis and Tuberculosis in a 19th Century Child Skeleton. *Journal of Anthropology*, 2015, 1-11.
- Ioannou, S., Sassani, S., Henneberg, M., Henneberg, R.J. (2016). Diagnosing congenital syphilis using Hutchinson's method: Differentiating between syphilitic, mercurial, and syphilitic-mercurial dental defects. *American Journal of Physical Anthropology*, 159, 617-629.
- Ioannou, S., Henneberg, M. (2016). A Rare Case of Congenital Syphilis and a Supernumerary Fourth Molar in an Early 20th Century African American Woman. *Dental Anthropology*, 29, 41-47.
- Kar, S.K., Tripathi, A., Singh, S.V. (2012). Full mouth rehabilitation of hypomaturation type amelogenesis imperfecta: A clinical report. *Journal of Oral Biology Craniofacial Research*, 2, 213-216.
- Lancet. (1917). The control of venereal diseases. *Lancet*, 189, 772-773.
- Lancet. (1921). Venereal disease in U.S.A. *Lancet*, 198, 863.
- Lancet. (1930). United States of America. *Lancet*, 215, 987-988.
- Lancet. (1937a). Venereal disease in the U.S.A: (From an occasional correspondent). *Lancet*, 229, 466-467.
- Lancet. (1937b). Treatment of syphilis. *Lancet*, 230, 759-760.
- Lancet. (1939). United States of America: (From an occasional correspondent). *Lancet*, 233, 1226-1227.
- Lancet. (1940). United States of America. *Lancet*, 236, 592.
- Lee, H. (1878). Note of the use of calomel vapour bath. *Lancet*, 111, 193-193.
- Lipski, J., Przyłipiak, S. (1959). W sprawie patomorfologii uzebie nia w kile wrodzonej. *Pol Tyg Lek*, 14, 524-528.
- McCarthy, F.P., Dexter Jr, S.O. (1935). Oral Manifestations of Bismuth. *New England Journal of Medicine*, 213, 345-353.
- Miller, J. (1858). Administration of mercury in syphilis: (Note from Professor Miller). *Lancet*, 71, 349-350.
- Moon, H. (1877). On irregular and defective tooth development. In: *Transactions of the Odontological Society of Great Britain vol. IX-New Series*. London: Wyman & Sons.
- Moon, H. (1884). Dental surgery. In: T Bryant, (eds). *A manual for the practice of surgery*. London: J & A Churchill.
- Muñoz, M.A., Arana-Gordillo, L.A., Gomes, G.M., Gomes, O.M., Bombarda, N.H., Reis, A., Loguercio, A.D. (2013). Alternative esthetic management of fluorosis and hypoplasia stains: blending effect obtained with resin infiltration techniques. *Journal of Esthetic and Restorative Dentistry*, 25, 32-39.
- Nakashima, A.K., Rolfs, R.T., Flock, M.L., Kilmarx, P., Greenspan, J.R., Greenspan, J.R. (1996). Epidemiology of Syphilis in the United States, 1941-1993. *Sexually Transmitted Diseases*, 23, 16-23.
- Nelson, S.J., Ash, M.M. (2010). *Wheeler's dental anatomy, physiology and occlusion*. St Louis, MI: Saunders Elsevier.
- Prasad, M.K., Laouina, S., El Alloussi, M., Dollfus, H., Bloch-Zupan, A. (2016). Amelogenesis Imperfec-

- ta: 1 Family, 2 Phenotypes, and 2 Mutated Genes. *Journal of Dental Research*, 95, 1457-1463.
- Prebble, E.E. (1938). Observations of venereal disease in the United States of America. *Lancet*, 232, 1037-1040.
- Roberts, C. (2011). The Bioarchaeology of Leprosy and Tuberculosis. In S. C. Agarwal and B. A. Glencross (Eds), *Social Bioarchaeology* (pp. 252-282). Oxford: Wiley-Blackwell.
- Roffey, S., Tucker, K. (2012). A contextual study of the medieval hospital and cemetery of St Mary Magdalen, Winchester, England. *International Journal of Paleopathology*, 2, 170-180.
- Rogers, H.G., Yesudian, G., Rodd, H.D. (2016). Unusual extrinsic staining following microabrasion in a girl with amelogenesis imperfecta. *European Archives of Paediatric Dentistry*, 17, 271-275.
- Scheer, M., Fraser J. F. (1930). New York Academy of Medicine, section of dermatology. *Archives of Dermatology and Syphilology*, 22, 520-529.
- Sherwood, I.A. (2010). Fluorosis varied treatment options. *Journal of Conservative Dentistry*, 13, 47-53.
- Smith, S.T. (1844). On the treatment of secondary syphilis by mercury. *Lancet*, 43, 556.
- Sunny, S.D., Israt, B., Saha, A.K., Dithi, A.B., Illius, F. (2013). Oral health of the arsenic exposed and non-exposed children in Bangladesh. *City Dental College Journal*, 10, 5-8.
- Švejšda, J. (1952). Zmeny na zubech pri kongenitalni syfilis. *Cesk Stomatology*, 52, 321-341.
- United States. Public Health Service. Division of Venereal Diseases. (1930). *Congenital syphilis : abstracts secured in the compilation of "Venereal disease information" and on file in the Division of venereal diseases ; Compilation No .2, (Rev. June, 1930) ; issued by the United States Public Health Service for the use in its cooperative work with the state health departments / Taliaferro Clark, assistant surgeon general, chief, Division of venereal diseases. Washington, DC: United States Government Printing Office.*
- Warner, F. (1881). East London hospital for children: Cases of congenial syphilis. *Lancet*, 117, 173-174
- Wakerlin, G.E. (1934). Colloidal mercury sulphide in the treatment of syphilis. *Archives of Dermatology and Syphilology*, 30, 49-58.
- Weatherill, T. (1833). Extraordinary ravages of syphilis and mercury on the human countenance. *Lancet*, 20, 357-359.
- Wilson, R.H., Deeds, F. (1939). Experimental chronic cadmium poisoning. *Science*, 90, 498.
- World Health Organization. (2012). *Leprosy: fact sheet no. 101*. World Health Organization, Geneva, Switzerland. <http://www.who.int/mediacentre/factsheets/fs101/en/>. Viewed 3 June, 2017.
- Youravong, N., Chongsuvivatwong, V., Teanpaisan, R., Geater, A.F., Dietz, W., Dahlén, G., Norén, J.G. (2005). Morphology of enamel in primary teeth from children in Thailand exposed to environmental lead. *Science of the Total Environment*, 348, 73-81.
- Zambrano, M., Nikitakis, N.G., Sanchez-Quevedo, M.C., Sauk, J.J., Sedano, H., Rivera, H. (2003). Oral and dental manifestations of vitamin D-dependent rickets type I: Report of a pediatric case. *Oral Surgery, Oral Medicine, Oral Pathology, Oral Radiology, and Endodontology*, 95, 705-709.
- Zuckerman, M. (2016). More harm than healing? Investigating the latrogenic effects of mercury treatment of acquired syphilis in post-Medieval London. *Open Archaeology*, 2, 42-55.

## BOOK REVIEW

*What Teeth Reveal About Human Evolution.* Debbie Guatelli-Steinberg. Published in Cambridge by Cambridge University Press, 2016. pp. 287. Illus. Indexed. ISBN 978-1-118-84543-1, Price: US\$54.99 (paperback); ISBN 978-1-107-44260-3.

As some of the most durable tissues of the skeleton, teeth are often better preserved than much of the rest of the body and represent more common fossil finds at paleoanthropological sites. In addition, they provide a plethora of information about biological or phylogenetic relationships, dietary reconstruction, growth and development, and decay. “What Teeth Reveal about Human Evolution” is an accessible account of what we can, and have, learned from studying teeth across the fossil and skeletal record of our hominin ancestors. Writing in a friendly and personal style, Debbie Guatelli-Steinberg presents the long history of the human lineage from the earliest hominins to modern humans through their teeth. The book is laced with her understanding of this extensive and often contested history and is informed by her own work throughout.

The book is divided into two sections based on broad temporal or genera distinctions, that is, early versus late hominins, or Australopithecines (and *Paranthropus*) versus *Homo* species. Within these major divisions each of the ten chapters addresses the defining characteristics and primary information that teeth have informed us about fossil species, crafting the larger story of the interpretations about the evolution of hominins. Chapter 1 builds the background about what teeth can tell us from fossil specimens and introduces the broad sweep of our evolutionary history. This is followed by a focus on the Australopithecines and Paranthropines, how they lived, and what they ate. Chapter 3 pays special attention to the issue of canines, and what they mean in these early species with regard to diet, jaw architecture, and sexual selection. Chapter 4 closes out the first part of the book by delving into how we know that juvenile growth periods were much faster among early hominins than among modern humans. The second part of the book opens with a similar introduction and outline for the evolution of the genus *Homo*. Chapter 6 focuses on the interrelationships between tooth size, diet, and the beginning of an evolution of culture across early *Homo* species.

Chapter 7 again returns to issues of development as among the Australopithecines, but also introduces longevity for early *Homo*. Chapters 8 and 9 focus on the diversity of information gained from studying Neanderthal and modern *Homo sapiens* teeth respectively. These chapters address issues like origins and phylogeny, diet and dental disease, and adaptations and life history. The final chapter serves to summarize the book’s main points and bring Dr. Guatelli-Steinberg’s appreciation for, and perspective on, our dental evolution to the present, and into the future for dental paleoanthropology.

The book is designed for undergraduates and non-professionals, but I think that it provides sufficient detail across the breadth of hominin dental studies that it would also offer a good reference piece for professionals and academics that focus on related research topics. “What Teeth Reveal about Human Evolution” is ambitious in its consideration of a significant diachronic perspective (~7 my), the ability to introduce and integrate the variety of perspectives that paleo-dental studies can provide, and the capacity to translate and collate that information for an audience generally lacking specialized knowledge. This book would work well in undergraduate courses on human evolution and as a supplementary companion to graduate seminars in related topics.

JAMES T. WATSON, Ph.D.  
ARIZONA STATE MUSEUM  
THE UNIVERSITY OF ARIZONA

## BOOK REVIEW

*Holocene Foragers of North India: The Bioarchaeology of Mesolithic Damdama*. By John R. Lukacs and Jagannath Pal, with contributions by M.C. Gupta, V.D. Misra, Greg C. Nelson, and G. Robbins Schlug. Published in Oxford by British Archaeological Reports Ltd, 2016. pp. 328. ISBN: 978-1-4073-1452-5, price £49.00, or A\$63.15

In bioarchaeology, little attention has been paid to the Indian subcontinent, especially compared to the volume of work on Native Americans and Europeans. *Holocene Foragers of North India: The Bioarchaeology of Mesolithic Damdama* contributes to the scholarship relating to the Mesolithic Lake Culture (MLC) of Northern India and helps expand the corpus of bioarchaeological work in India.

Lukacs and Pal explore the life of the residents of Damdama through a comprehensive analysis of human remains. The site of Damdama, discovered in 1978, constitutes the third major Mesolithic site in the region to yield a high number of artifacts in association with human remains. To an extent, the bioarchaeology of South Asia has been limited by the poor preservation of human remains, resulting in a focus on the individual rather than the population. However, the Damdama assemblage exhibits uncharacteristically good preservation, allowing Lukacs and Pal to address population-driven questions. Additionally, the position of Lukacs as an author makes this volume unique among studies of Mesolithic Lake Culture peoples, as he studied the other two major MLC sites (Sahar Nahar Rai and Mahadaha). This volume involves comparisons among the three sites so potential interobserver biases are minimized. Intersite comparisons allow for a discussion of the place of Damdama among MLC peoples, and puts the Indian MLC in a larger global context. This assemblage is comprised of 46 well-preserved individuals, allowing researchers to evaluate variables relating to diet, health, stress, activity levels, and the genetic characteristics of the residents of Mesolithic Damdama. To that end, chapters 9-11 focus on the wealth of information derived from the dentition. Chapter 9 focuses on the dental inventory of the assemblage and provides information on the prevalence and degree of tooth wear. The dental inventory is an easily overlooked component of an analysis, but the authors emphasize that understanding sample composition is necessary to recognize potential

limitations and biases of subsequent analyses. Dental wear was scored using the quadrant system of E. Scott (1979) and the Eight Grade System of Langsjoen (1998). Each system is discussed, highlighting its advantages and disadvantages, and noting the appropriate circumstances for implementation. Ultimately, the combination of dental wear scores, and derived variables led the authors to conclude that the inhabitants of Damdama, like other MLC peoples, consumed a coarse diet and were subject to heavy masticatory stresses.

The pattern of dental wear in the Damdama sample was additionally used to support the conclusion that this population subsisted using a hunting-foraging strategy. The authors present a unique use of the quadrant wear system (Scott 1979) to assess the angle of molar wear as proposed by Smith (1984). Smith (1984) asserts that hunter-foragers tend to demonstrate a flatter molar wear plane, while agricultural populations show steeper planes of molar wear. To evaluate molar wear angle, Lukacs and Pal suggest wear scores of the lingual cusps can be compared to the buccal cusps – the greater the difference in wear scores, the more steeply angled the molar wear plane. The authors recognize this analysis may not be precise enough to capture subtle angle differences, but the combination of these two classic dental wear techniques is intriguing and represents an exciting new possibility for future dental anthropological studies.

The focus of chapter 10, dental pathology, includes the prevalence of oral lesions and interpretations of their significance. The study of dental pathology is critical to any comprehensive bioarchaeological research project as it provides a snapshot of the diet and dietary behavior of past populations. In this chapter, the broad category of dental pathology includes developmental anomalies, infectious diseases, and degenerative conditions. We commend the authors on their explicit definitions of pathological conditions to ensure clarity to the reader and replicability in future research. Dental pathology is explored in several contexts. First, frequencies of a given condition are presented by individual and by sex to discern patterns within these divisions. Next, the rates of pathologic manifestations are compared between Damdama and other hunter-forager and agriculturist groups to explore the effects of subsistence on pathology. After a discussion of the prevalence of enamel hypoplasia, the chapter concludes with an interpretation of the suite of conditions observed in the Damdama sample. In total, the profile of the residents of Damdama derived from an analysis of dental pathology is consistent with a hunter-forager population with a diet of coarsely textured

food. Rates of caries and periapical lesions are remarkably low, and rates of antemortem tooth loss are moderate on a world scale. Enamel hypoplasias are common in this population, suggesting periods of childhood stress; however, post-cranial analyses of adult stature suggest these childhood stress episodes were not severe.

The final chapter (11) focuses on the morphology and metrics of the Damdama dentition. These data are used to explore the functional aspects of tooth size and morphology, as well as their utility in assessing population affinity. The sample available for the study of morphology was too small to be statistically robust; therefore, for discussions of morphology, the Damdama individuals were grouped into a larger Mesolithic Lake Culture group. The dental morphology of the MLC population is best described as simple. Although incisor shoveling occurs with moderate frequency, few other mass-additive features were observed. Bio-distance analyses based on dental morphology align the collective Mesolithic Lake Culture people with the generalized Sundadont (Turner 1990) and Indodont (Hawkey 1998) dental patterns. Furthermore, these analyses reveal previously unidentified linkages between the peoples of the MLC and extant tribes. The analysis of tooth size is also revealing. The trend in tooth size at Damdama is toward larger dentitions, exhibiting some of the largest teeth in all of South Asia. The authors offer increased tooth size as support of a hunter-forager subsistence pattern in the MLC. Taken together, the results of morphological and metric analyses of the Damdama teeth are consistent with inferences of diet and subsistence derived from tooth wear and dental pathology.

Lukacs and Pal are to be commended for their comprehensive examination of the bioarchaeology of the Damdama site in northern India, particularly the thorough treatment of the dentition. This work represents the full-complement of a dental anthropologist's contribution to the bioarchaeological literature. Their focus on population-driven questions and quantitative methods represents the future of bioarchaeological research. The acknowledgment by these authors of potential biases and limitations throughout their research strengthens the final product. Knowledge of potential problems helps the reader temper any conclusions drawn from this work. The authors set three goals for the volume: 1) to elucidate the utility of bioarchaeology in understanding prehistoric human behavior, 2) to explore the place of Mesolithic hunter-foragers in the regional archaeological sequence, and 3) to approach the bioarchaeological data in an integrative and synthetic way in researching the MLC of North India. They achieve

all three goals. This volume represents an exceptional standard for bioarchaeological work and shows how the dentition informs bioarchaeological questions and provides direction of future research in South Asia.

CHRISTOPHER A. MAIER<sup>1</sup>, Ph.D.; KELLY N. HEIM<sup>2</sup>, M.A.; and G. RICHARD SCOTT<sup>2</sup>, Ph.D.

<sup>1</sup>ECKERD COLLEGE

<sup>2</sup>UNIVERSITY OF NEVADA, RENO

#### LITERATURE CITED

- Hawkey DE. (1998). Out of Asia: Dental Evidence for Affinities and Microevolution of Early Populations from India/Sri Lanka. PhD Dissertation. Arizona State University, Tempe, AZ.
- Langsjoen O. (1998). Dental pathology. In: Aufderheide AC and Rodríguez-Martín C, (eds). *The Cambridge Encyclopedia of Human Paleopathology*. Cambridge, UK: Cambridge University Press, pp. 393-412.
- Scott EC. (1979). Dental wear scoring technique. *American Journal of Physical Anthropology*, 51, 213-218.
- Smith BH. (1984). Patterns of molar wear in hunter-gatherers and agriculturalists. *American Journal of Physical Anthropology*, 63, 39-56.
- Turner CG II. (1990). Major features of Sundadonty and Sinodonty, including suggestions about East-Asian microevolution, population history, and Late Pleistocene relationships with Australian Aborigines. *American Journal of Physical Anthropology*, 82, 295-317.



## EDITORS' CORNER

### **New Website for Journal**

We are pleased to announce the official launch of the new website for the journal! Authors can now submit manuscripts via the Dental Anthropology Association website at the following link:

[journal.dentalanthropology.org](http://journal.dentalanthropology.org).

Hopefully, this move will ease manuscript submission for authors and streamline the peer review process. This website will also serve to house all the back issues of the journal. This move should make it easier to find content published in the journal and increase its visibility.

We would like to reiterate our commitment to open access and accessibility of the journal and the research housed within. All content will continue to be made available free of charge.

As the editors, we are excited about the direction of the journal, and look forward to reading future submissions.

MARIN A. PILLOUD and G. RICHARD SCOTT

# Dental Anthropology

Volume 30, Issues 01, 2017

## Research Article

### **Expression of Nonmetric Dental Traits in Western European Neanderthals**

Frank L'Engle Williams and Rebecca L. George 3

## Case Studies

### **Severe Plane-Form Enamel Hypoplasia in a Dentition from Roman Britain**

Ian Towle, Eleanor R. Dove, Joel D. Irish, Isabelle De Groot 16

### **Five Cases of Dental Anomalies Attributable to Congenital Syphilis from Early 20th Century American Anatomical Collections**

Stella Ioannou, David Hunt, and Maciej Henneberg 25

## Book Reviews

### **Book Review: *What Teeth Reveal About Human Evolution***

James T. Watson 38

### **Book Review: *Holocene Foragers of North India: The Bioarchaeology of Mesolithic Damdama***

Christopher A. Maier, Kelly N. Heim, G. Richard Scott 39

## Editors' Corner

### **New Website for Journal**

Marin A. Pilloud and G. Richard Scott 41

Published at:

The University of Nevada, Reno

1664 North Virginia, Reno, Nevada, 89557-0096 U.S.A

The University of Nevada, Reno is an EEO/AA/Title IX/Section 504/ADA employer