

Dental Anthropology

A Publication of the Dental Anthropology Association



Dental Anthropology

Volume 19, Number 3, 2006

Dental Anthropology is the Official Publication of the Dental Anthropology Association.

Editor: Edward F. Harris

Editorial Board

Kurt W. Alt (2004-2009)

A. M. Haeussler (2004-2009)

Tseunehiko Hanihara (2004-2009)

Kenneth A. R. Kennedy (2006-2010)

Jules A. Kieser (2004-2009)

Richard T. Koritzer (2004-2009)

Helen Liversidge (2004-2009)

Yuji Mizoguchi (2006-2010)

Lindsay C. Richards (2006-2010)

Phillip W. Walker (2006-2010)

Officers of the Dental Anthropology Association

Simon W. Hillson (University College London) President (2006-2008)

Brian E. Hemphill (California State University, Bakersfield) President-Elect (2006-2008)

Heather H. Edgar (Maxwell Museum of Anthropology, NM) Secretary-Treasurer (2003-2006)

Debbie Guatelli-Steinberg (Ohio State University, OH) Past-President (2004-2006)

Address for Manuscripts

Dr. Edward F. Harris

College of Dentistry, University of Tennessee
870 Union Avenue, Memphis, TN 38163 U.S.A.

E-mail address: eharris@utmem.edu

Address for Book Reviews

Dr. Greg C. Nelson

Department of Anthropology, University of Oregon
Condon Hall, Eugene, Oregon 97403 U.S.A.

E-mail address: gcnelson@oregon.uoregon.edu

Published at

Craniofacial Biology Laboratory, Department of Orthodontics
College of Dentistry, The Health Science Center
University of Tennessee, Memphis, TN 38163 U.S.A.

The University of Tennessee is an EEO/AA/Title IX/Section 504/ADA employer

Paramolar tubercle in the left maxillary second premolar: a case report.

Carolina Rodríguez¹ and Freddy Moreno^{2*}

¹Department of Orthodontics and ²Oral and Maxillofacial Surgery Research Group (Dental Anthropology and Forensic Dentistry), School of Dentistry, University of Valle, Cali, Colombia.

ABSTRACT: This is a case report describing a paramolar tubercle occurring on the buccal surface of left upper second premolar (tooth 25). From the perspective of

dental anthropology, this morphological feature, though uncommon, may be useful for classification and identification. *Dental Anthropology* 2006;19(3):65-69.

Dental anthropology can be viewed as the collaborative effort of anthropology, clinical dentistry, biology, paleontology, and paleopathology. The resulting knowledge base permits the study, analysis, interpretation, and understanding of information derived from the human dentition through their morphological, evolutionary, pathological, cultural and therapeutic variations. These structural considerations are viewed against a people's culture, notably the conditions of life, diet, and adaptation processes. The varied sorts of data studied include nonmetric traits, metric traits, oral and dental diseases, and structural modifications of the teeth. Dental morphology, particularly the study of nonmetric dental traits (NDT), involves genetically-modulated trait expressions that can be used for comparisons within and among populations (Scott and Turner, 1997, 1998; Rodríguez CD, 2003, 2005; Rodríguez and Delgado 2000; Rodríguez JV, 2003).

More than 100 NDT of dental crowns and roots have been described and standardized internationally using various methodologies. Their study and investigation have demonstrated that: (a) they possess high taxonomic value; (b) they can be used to estimate biological relationships among diverse populations, which allows comparative analyses of the historical, cultural and biological development of primitive and modern human groups; (c) most NDT have low sexual dimorphism, low correlations among features, and low correspondence between frequency and geography; (d) they are easily observed and recorded; and (e) they can be used to evaluate population differences according to micro-evolutionary processes, that, in turn, generate information about human movements and contacts that have produced groups' ethnic variation (Scott and Turner, 1997; Zoubov, 1997; Rodríguez JV, 2003).

Within the broad study of dental morphology, one feature that stands out is the tubers paramolares. These NDTs are not common, and, especially in the clinical

dental literature, they are viewed as supernumerary cusps or ill-defined anatomical variations. Basically, paramolar tubercles occur as accessory cusps located on the buccal or lingual surface of the primary and succedaneous teeth, involving both the maxillary or mandibular tooth types. Several of these morphological variants are broadly recognized in the dental anthropological literature, such as the dental tubercle on the lingual surface of the upper lateral incisors; the Uto-Aztecian or distosagittal crest on the buccal surface of the upper first premolar; Carabelli's trait on the lingual surface of the mesolingual cusp of the upper molars; the parastyle on the buccal surface of the upper molars; the protostylid on the buccal surface of the low first molars; and paramolar tubercles, generally developed on the buccal surfaces of the upper and low premolars and molars (Zoubov, 1997; Turner and Harris, 2004).

PARAMOLAR TUBERCLES

One NDT that has been described as an accessory or supernumerary cusp, was defined by A. A. Dahlberg in 1950 as a paramolar tubercle, a term applied nonspecifically to a style or cusp of supernumerary character that is developed on the buccal or lingual surfaces of the upper and low premolars and molars (Turner and Harris, 2004).

Developmentally, dental cusps begin their formation during the early bell stage, well before calcification of the tooth has begun. The cells of the internal epithelium proliferate and produce activators and inhibitors while they are being deposited in sequential layers from the

*Correspondence to: Freddy Moreno, Universidad del Valle - Sede San Fernando, Escuela de Odontología, Calle 4B No. 36-00 Edificio 132 Oficina 308. A.A. 25360, Cali - Colombia
E-mail: freddyodont@hotmail.com

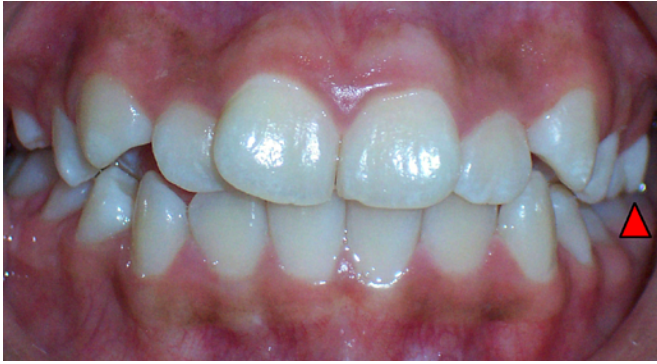

Fig. 1. Clinical front view: paramolar tubercle on the left maxillary second premolar (arrow).

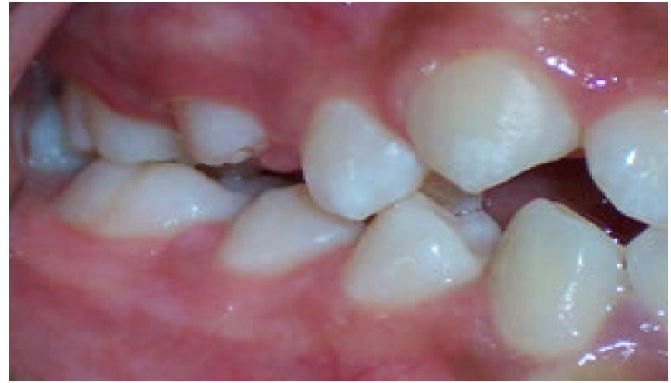

Fig. 2. Clinical right view. where the premolars lack any evidence of a tubercle.

cuspid apex toward the neck of the crown starting from an enamel knot. The activator produces a primary enamel knot until the concentration reaches a threshold that induces an inhibitor that neutralizes the activator. Once a primary enamel knot has developed, it subsequently disappears by means of apoptosis and secondary enamel knots may appear. Molecular biologists are beginning to understand the genes that code and control the expression of the activator and the inhibitor that modulate the rhythm and quantity of enamel deposition. These transient gene expressions modulate the formation and elevation of the peaks and crests leaving among them furrows and grooves.

Consequently, the formation of a NDT (a cusp, for example) begins with primary or secondary enamel knot. The form of the NDT is influenced by the amount (thickness) of enamel deposited, size of the crown, its relationship with other NDT, and its internal relationship with the dentine. The NDT's configuration depends, on one hand, on the molecular patterns that are genetically determined and, on the other hand, on the trait's relationship with other morphological features

(Butler, 1995; Jernvall *et al.*, 1994; Jernvall and Jung, 2000; Jernvall and Thesleff, 2000; Line, 2001; Thesleff and Sharpe, 1997).

Dental studies in the field of the molecular biology derive in part from the work of Thesleff *et al.* (*e.g.*, 2001). Research demonstrates that the primary enamel knot configures the occlusal table of premolars and molars, while secondary enamel knots individually constitute the cusps during amelogenesis (Thesleff, 2003; Turner and Harris, 2004).

In the case of the paramolar tubercle, Turner and Harris (2004) suggest that such cusps arise during the morphogenesis process starting from an accessory enamel knot developed at the surface where the feature's apex forms. It seems that these tubercles do not provide any functional adaptation, such as enlarging the occlusal (masticatory) surface, because these tubercles do not enter into function; they do not occlude against any cusp or groove of the antagonist tooth.

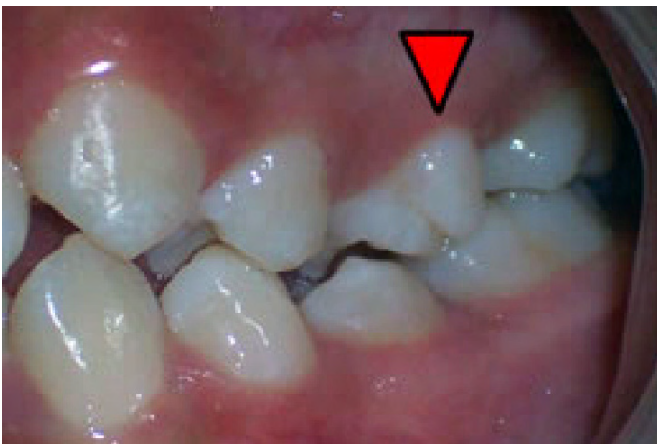


Fig. 3. Clinical right view: paramolar tubercle on the left maxillary second premolar (arrow).

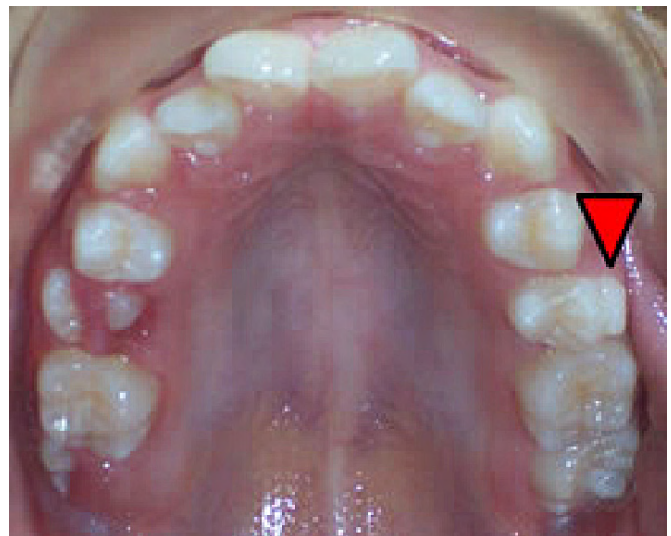


Fig. 4. Clinical occlusal view: paramolar tubercle on the left maxillary second premolar (arrow).

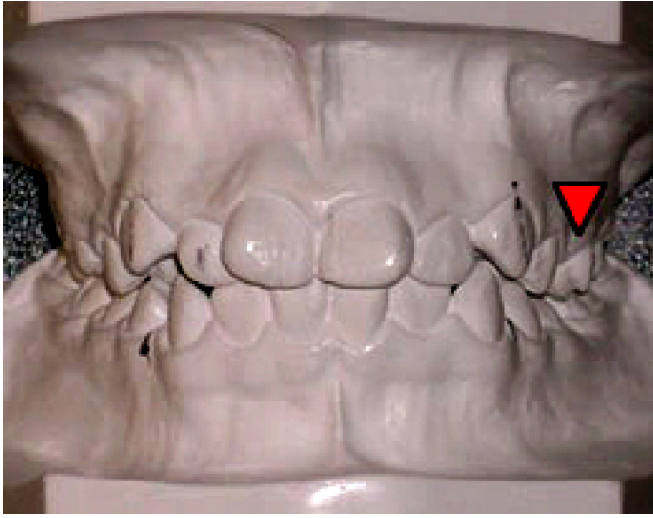


Fig. 5. Clinical frontal view of the articulated study models: paramolar tubercle on the left maxillary second premolar (arrow).

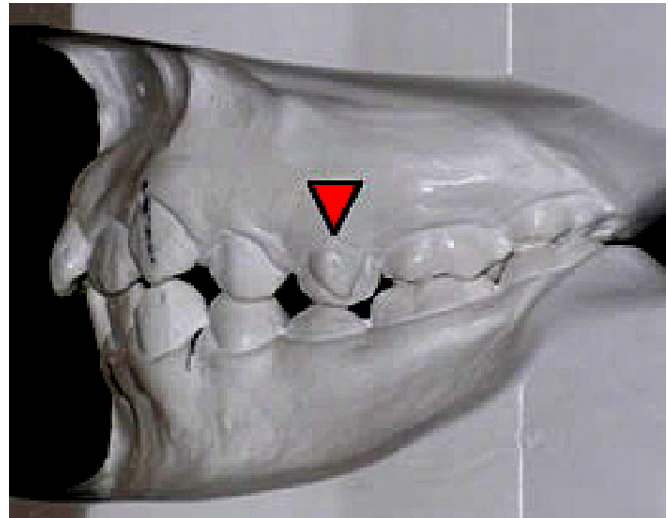


Fig. 6. Left view of the articulated study models: paramolar tubercle on the left maxillary second premolar (arrow).

To date, there is very little information about racial differences in the frequencies of paramolar tubercles, primarily because of their apparently low occurrence overall. Likewise, no pedigree analysis seems to have been conducted, though their mode of inheritance seems to be complex. Alternatively, their expression may suggest a genetic relationship between individuals. For instance, if the tubercle were found in two coeval individuals in a population, this increases the likelihood that the persons are genetically related, which can be useful for forensic identification (Zoubov, 1997; Edgar, 2005).

CASE REPORT

The subject is an eleven-year-old girl attending the orthodontic clinic at the School of Dentistry of the University of the Valley, Colombia.

Assessment of the maxillofacial skeleton disclosed a slight Class II sagittal molar relationship; upper and low arches were of an oval form; there was slight mandibular retrognathism; the facial form was mesofacial and there was a vertical growth pattern. Diagnosis of the soft tissue showed a convex facial profile, a moderate mentolabial furrow, a normal nasolabial angle, protrusion of both the upper and lower lips, and an increased height of the inferior third of the face. The stomatognathic functional diagnosis disclosed bruxism and a preference for unilateral right mastication. The dental diagnosis

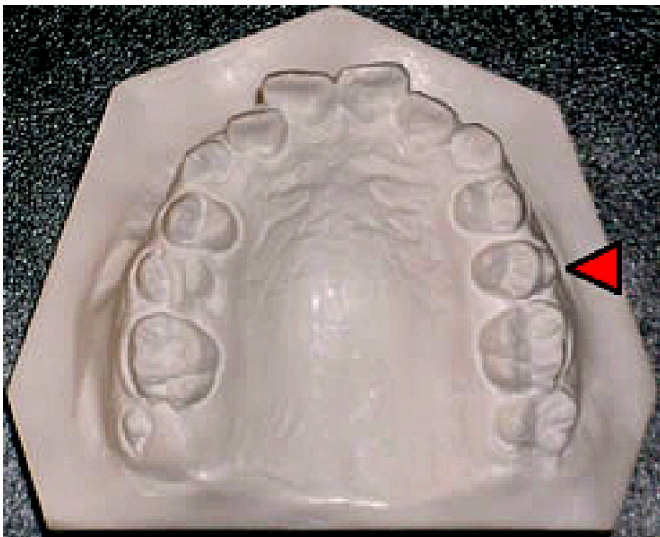


Fig. 7. Occlusal view of the maxillary study model: paramolar tubercle on the left maxillary second premolar (arrow).

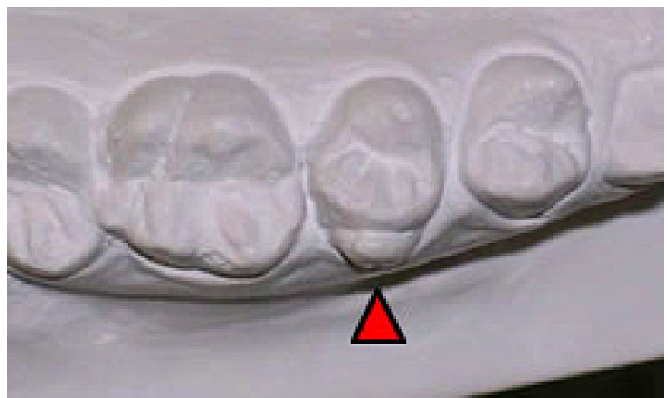


Fig. 8. Occlusal view of the maxillary study model: paramolar tubercle on the left maxillary second premolar (arrow).

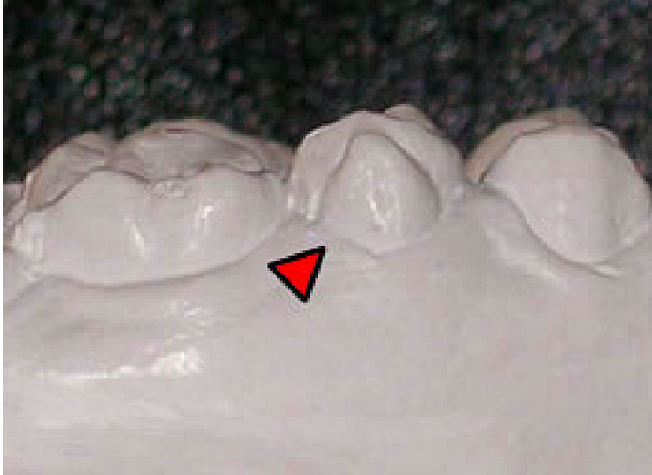


Fig. 9. Buccal view of the maxillary study model: paramolar tubercle on the left maxillary second premolar (arrow).

showed that the girl presents a complete permanent dentition (omitting the third molars), a Class I molar malocclusion, a Class II canine relationship, proclination of the mandibular incisors, moderate crowding in both arches, deviation of the dental midlines, and traumatic occlusion.

This NDT of interest here is a unilateral paramolar tubercle that on the buccal surface of the upper left second premolar. Viewed in the frontal plane (Figs. 1, 5), the tubercle presents a free cusp apex that does not reach the occlusal plane. Indeed, the tubercle is out of function since there is no occluding anatomical structure on the opposing mandibular teeth. In buccal view (Figs. 3, 6, 9), the tubercle constitutes a triangular prominence with its base below the gingival margin and its apex oriented occlusally. This cusp is aligned with that of the premolar's buccal cusp. From the occlusal view (Figs. 4, 7, 8), one can appreciate the symmetrical prominence of the tubercle, which is centered mesiodistally along the tooth's buccal surface. The longitudinal furrow is evident here, and it runs mesial to distal, separating the tubercle from the premolar's primary cusp.

Other NDTs that can be appreciated in the patient are: (A) Crowding of the upper incisors (Figs. 4, 7), where the lateral incisors are lingually displaced and there is a consequent tooth-size to arch-size discrepancy (Rodríguez, 1989; Bernabé and Flores, 2006). (B) Slight incisor winging (Figs. 4, 7), where both upper central incisors are slightly rotated distolingually relative to the midline; in this case, winging probably is secondary to inadequate arch space for correct incisor alignment (Peck and Peck, 1975; Rodríguez JV, 1989, 2003; Turner *et al.*, 1991; Nandini *et al.*, 2005; Bernabé and Flores, 2006). (C) Cusp 7 (grade 5) occurs bilaterally, which is an NDT characteristic of Negroid populations (Zoubov, 1997). (D) Cusp 6 (grade 2) occurs bilaterally. (E) A deflecting

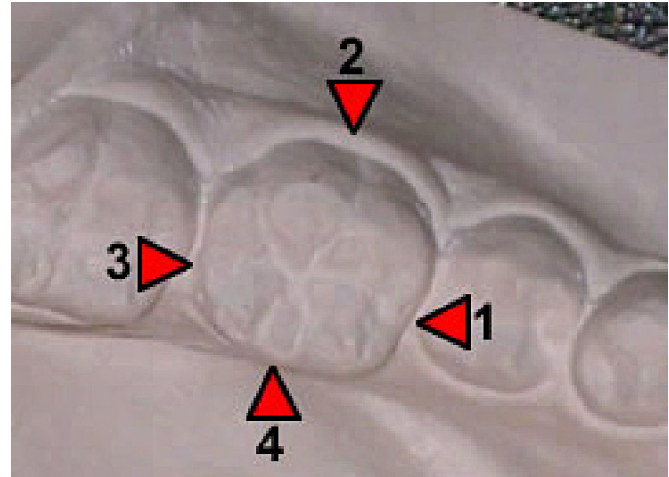


Fig. 10. Numerical codes are: (1) deflecting wrinkle; (2) protostylid; (3) cusp 6; and (4) cusp 7.

wrinkle (grade 3) can be seen on the first molars. (F) The molar cusp arrangement yields a Y6 groove pattern (mesiolingual cusp contacts with the distobuccal cusp at the central groove). (G) A protostylid pit occurs bilaterally (Fig. 10), which is a common NDT in mixed population from Colombia (Moreno *et al.*, 2004; Moreno and Moreno, 2005; Aguirre *et al.*, 2006).

RECOMMENDATIONS

It is important to recognize that although some NDTs, including the paramolar tubercles, only occur in low frequencies, they should not be classified as anomalous (a perspective common in clinical dentistry) since they are normal morphological features of the dentition. This morphological variation is evidenced by the diverse trait frequencies among world populations. Of course, this variability often is capitalized on in the processes of an individual's forensic identification.

It should be noted that, during orthodontic treatment, paramolar tubercles often are removed by ameloplasty (*i.e.*, the selective removal of enamel by grinding) because they interfere with cementation of the brackets and correct alignment of orthodontic archwires. However, this clinical procedure should be considered a last option, since it involves the mutilation of an epigenetic variant of the dental morphology.

It is important that NDTs are described systematically (by form and position) in each person's clinical dental history because these variants are of discriminatory value and because of their usefulness in the identification processes carried out during the technical and scientific exercise of forensic dentistry.

LITERATURE CITED

Aguirre L, Castillo D, Solarte D, Moreno F. 2006. Frequency and variability of five non-metric dental

- crown traits in the primary and permanent dentitions of a racially mixed population from Cali, Colombia. *Dental Anthropology* 19:39-47.
- Bernabé E, Flores-Mir C. 2006. Dental morphology and crowding: a multivariate approach. *Angle Orthod* 76:20-25.
- Butler PM. 1995. Ontogenetic aspects of dental evolution. *Int J Dev Biol* 39:25-34.
- Edgar HJ. 2005. Prediction of race using characteristics of dental morphology. *J Forensic Sci* 50:1-5.
- Jernvall J, Kettunen P, Karavanova I, Martin LB, Thesleff I. 1994. Evidence for the role of the enamel knot as a control center in mammalian tooth cusp formation. *Int J Dev Biol* 38:463-469.
- Jernvall J, Jung HS. 2000. Genotype, phenotype and developmental biology of molar tooth characters. *Yrbk Phys Anthropol* 43:171-190.
- Jernvall J, Thesleff I. 2000. Reiterative signaling and patterning during mammalian tooth morphogenesis. *Mech Develop* 92:19-129.
- Line S. 2001. Molecular morphogenetic fields in the development of human dentition. *J Theor Biol* 211:67-75.
- Moreno F, Moreno SM, Díaz CA, Bustos EA, Rodríguez JV. 2004. Prevalence and variability of eight non-metric dental traits in students of Cali, Colombia. *Colomb Med* 35(Supl 1):17-23. (In Spanish)
- Moreno SM, Moreno F. 2005. Eight non-metric dental traits in alive racially mixed population from Cali, Colombia. *Int J Dental Anthropol* 6:14-25.
- Nandini V, Utreja A, Goyal A, Chawla HS. 2005. Winged maxillary central incisors with unusual morphology: a unique presentation and early treatment. *Angle Orthod* 75:427-431.
- Peck S, Peck H. 1975. Orthodontic aspects of dental anthropology. *Angle Orthod* 45:95-102.
- Rodríguez CD. 2003a. Prehispanic dental anthropology: biological variation and distances in the population buried in the pre-hispanic cemetery of Obando, Valle del Cauca, Colombia between the centuries VIII and XIII A.D. Miami: Syllaba Press. (In Spanish)
- Rodríguez CD. 2005. Dental anthropology and your importance in the human groups study. *Rev Fac Odont Univ Ant* 16:52-59. (In Spanish)
- Rodríguez CD, Delgado ME. 2000. Dental anthropology: a brief definition. *Int J Dental Anthropol* 1:2-4.
- Rodríguez JV. 1989. Introducción a la antropología dental. Cuadernillo de antropología No. 19. Universidad Nacional de Colombia, Facultad de Ciencias Humanas, Departamento de Antropología. Santa fe de Bogotá.
- Rodríguez JV. 2003. Teeth and human diversity: dental anthropology advances. Bogotá: Universidad Nacional of Colombia. (In Spanish)
- Scott GC, Turner II CG. 1997. The anthropology of modern human teeth: dental morphology and its variation in recent human populations. London: Cambridge University Press.
- Scott GC, Turner II CG. 1998. Dental anthropology. *Ann Rev Anthropol* 17:99-126.
- Thesleff I. 2003. Developmental biology and building a tooth. *Quintessence Int* 34:613-620.
- Thesleff I, Sharpe P. 1997. Signalling networks regulating dental. *Mech Develop* 67:111-123.
- Thesleff I, Keranen S, Jernvall J. 2001. Enamel knots as signaling centers linking tooth morphogenesis and odontoblast differentiation. *Adv Dent Res* 15:14-18.
- Turner CG II, Nichol CR, Scott GR. 1991. Scoring procedures for key morphological traits of the permanent dentition: the Arizona State University dental anthropology system. In: Kelly MA, Larsen CS, editors. *Advances in dental anthropology*. New York: Wiley-Liss Inc, p 13-31.
- Turner RA, Harris EF. 2004. Maxillary second premolars with paramolar tubercles. *Dental Anthropology* 17:75-78.
- Zoubov AA. 1998. The dental anthropology and de forensic practice. *Maguaré* 13:243-252. (In Spanish)

Brief Communication: Rotation of the Maxillary Premolars: Evidence in Support of Premolar Morphogenetic Field

Vincent H. Stefan*

Department of Anthropology, Herbert H. Lehman College, CUNY, Bronx, NY 10468

ABSTRACT: The presence of an individual tooth, axially rotated within the maxillary and/or mandibular dental arcade is not an uncommon occurrence in the human dentition. Far rarer is the axial rotation of two or more adjacent teeth, rotated together as a "unit" within the dental arcade. Two rare cases are presented here, each

case possessing a maxillary P3-P4 unit that has been axially rotated. This event is in and of itself interesting and important, yet it also potentially provides support for the concept of a "premolar" morphogenetic field. *Dental Anthropology* 2006;19(3):70-73.

Dental morphological variation can be considered to fall within two broad categories: (1) those that involve major deviations from the basic dental blueprint and (2) those that involve minor, subtle variations in crown and/or root morphology (Hillson, 1996; Scott and Turner, 1997). Included within the first category are such dental anomalies as supernumerary teeth (polygenesis or polydontia), missing one or more teeth (agenesis or hypodontia), fusion of adjacent teeth, transposition of teeth, rotation of teeth, malposition of teeth, deviations from the "normative" crown morphology (e.g., conical lateral incisors, 3-cusped upper premolars, "mulberry" molars) and other sundry anomalies. The second category of dental variation includes minor variations in secondary cusps, fissure patterns, marginal ridges, supernumerary roots, and so forth (Scott and Turner, 1997:3). Many of the dental anomalies in the first category involve developmental errors in the number and/or positions of individual tooth germs or tooth morphogenetic fields. However, the existence of dental morphogenetic fields has been debated (Henderson and Greene, 1975). Evidence illustrating an extremely rare form of dental rotation, as well as supporting the presence of a premolar morphogenetic field is discussed below.

SPECIMENS

Within the skeletal collection of the American Museum of Natural History, New York, are two specimens displaying a unique rotation of a maxillary P3-P4 unit.

CASE 1: AMNH 99.1/1395

The first case consists of well-preserved maxillary and mandibular dental arches of a specimen from the

collection of Marquesas Island crania collected by H. L. Shapiro during the Templeton Crocker Pacific Expedition in 1934 or possibly during his participation in the B. P. Bishop Museum Tuamotu Expedition in 1929. This specimen possesses a unique dental anomaly in which both the maxillary left P3 and P4 were mesially rotated 90°, as a unit (Figs. 1-2). Crown morphology of the premolars is completely normal. Also evident in the specimen's dentition is moderate shoveling of the central and lateral incisors, as well as a small expression of Carabelli's trait on the first maxillary molars. No other dental anomaly was noted.

CASE 2: AMNH 99/8478

The second case consists of well-preserved maxillary and mandibular dental arches of a specimen from the collection of Cañon del Muerto, Arizona crania collected by Earl H. Morris during an American Museum of Natural History expedition in 1923 and 1924. This specimen also possesses a unique dental anomaly in which both the maxillary right P3 and P4 were distally rotated ~80°, as a unit (Figs. 3-4). However, unlike the P4 of the AMNH 99.1/1395 specimen, the P4 of this specimen appears to have distally rotated an additional 180°. Crown morphology of the premolars is normal otherwise, though with a relatively large carious lesion on the distal surface on the P4 crown and root. Also evident in the specimen's dentition is shoveling of the central incisors, as well as the medial rotation of the central incisors. No other dental anomaly was noted.

*Correspondence to: Vincent H. Stefan, Department of Anthropology, Herbert H. Lehman College, CUNY, 250 Bedford Park Blvd. West, Bronx, NY 10468
E-mail: vincent.stefan@lehman.cuny.edu

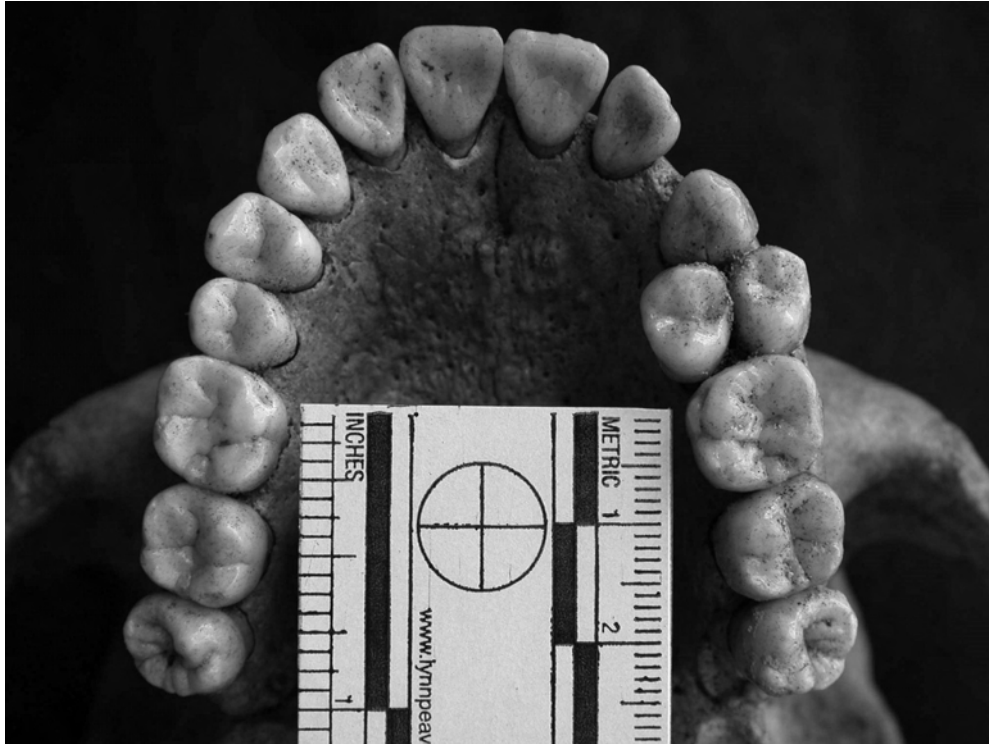

Fig. 1. Occlusal view of AMNH 99.1/1395 maxillary dentition.

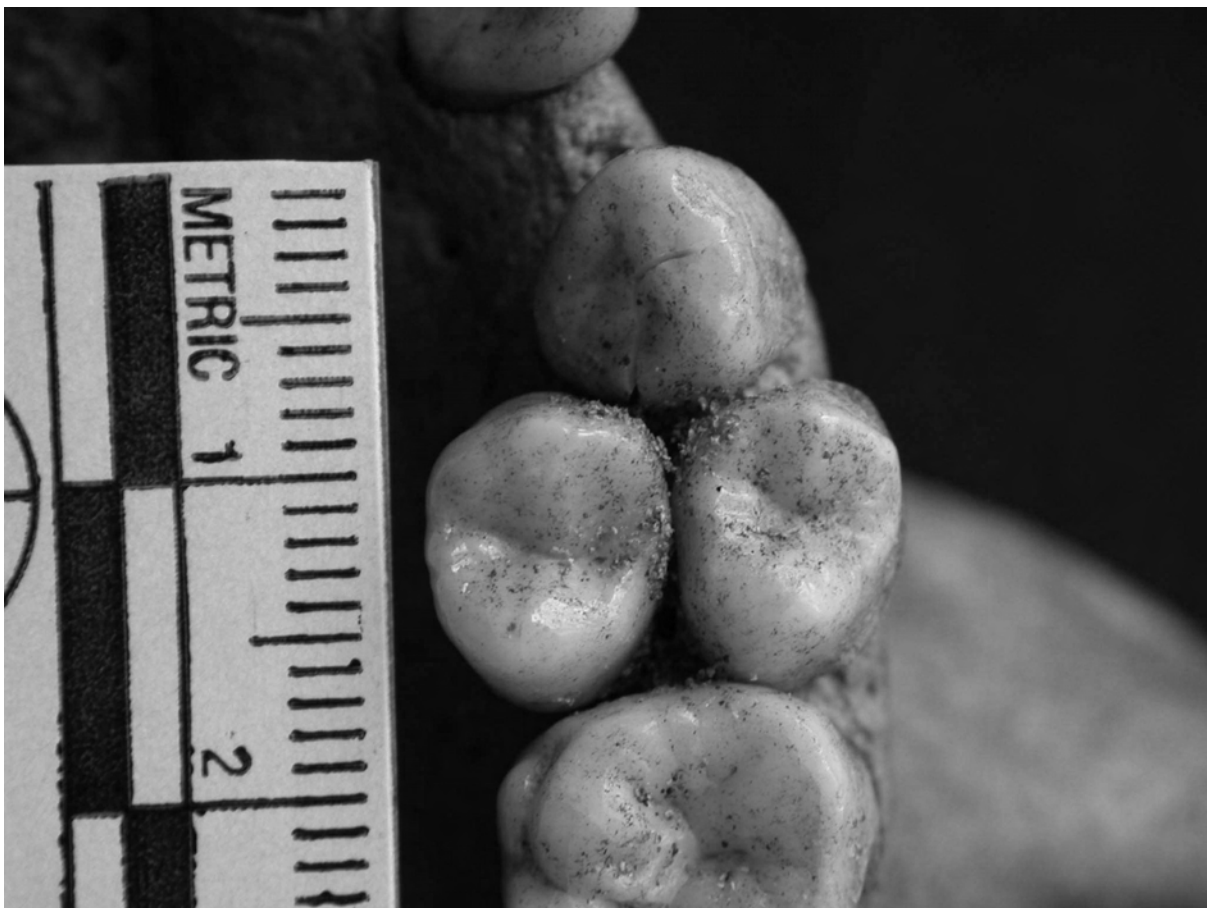

Fig. 2. Close-up view of left maxillary premolars of AMNH 99.1/1395.

DISCUSSION

Minor-to-pronounced axial rotation has been noted of individual teeth of the maxillary and mandibular dental arcade. The direction of this axial rotation can be either mesial or distal. Winging and counter-winged, either unilateral or bilateral, of the maxillary central incisors, seen predominantly in Native American Indians, is one example of a minor rotation of a tooth (Dahlberg, 1963; Escobar *et al.*, 1976). More pronounced axial rotation of an individual tooth typically involves a 90 to 180 degree rotation (Lui, 1980; Tay, 1968; van Nievelt and Smith, 1997). Normally, these cases of extreme axial rotation are also characterized by either unilateral or bilateral rotation of individual teeth.

However, the rare cases discussed above represent an even smaller sub-category of dental rotation, an occurrence where two adjacent teeth are rotated as a "unit" within the dental arcade. This type of dental rotation, to the author's knowledge, has not been documented or reported in the literature. These cases each possess a maxillary P3-P4 unit that has been either medially or distally rotated, an event in and of itself very interesting and important. Yet, these examples of P3-P4 unit rotation also potentially support the concept of a premolar morphogenic field.

Butler (1937; 1939) presented the concept that the gradients in mammalian dentition was due to morphogenic fields. He proposed that each tooth germ in the maxilla or mandible possessed the same genetic information, which would allow any single tooth germ to develop into any type of tooth. It was only the tooth germ's position in the maxilla or mandible that determined what type of tooth the tooth germ would ultimately develop into, directed by some field substance or morphogen (Scott and Turner, 1997). Butler hypothesized three morphogenic fields, namely incisor, canine and molar, and variations within each field were due to "pattern genes" operating at a secondary level on different tooth germs within a morphological field (Butler, 1937, 1939; Scott and Turner, 1997:82).

Butler's morphogenic field theory was applied to humans by Dahlberg (1945). In addition to Butler's three morphogenic dental fields, Dahlberg defined a fourth, "pre-molar" dental field. Dahlberg's separation of premolars from the molar morphogenic field into its own field, resulting in the definition of four morphogenic dental fields, nicely corresponded to the four morphological classes of teeth present in humans. Debate currently exists as to whether premolars should be distinguished as a dental field, separate from the molar field (Scott and Turner, 1997; Suarez and Williams, 1973; Townsend and Brown, 1981). Many dental anthropologists argue that premolars are an anterior extension of the molar dental field, while others note crown and root morphology that support the existence of a distinct premolar dental field (Scott

and Turner, 1997:84-85; Wood and Engleman, 1988; Wood *et al.*, 1988). Scott and Turner (1997:85) state, "To summarize, the evidence is equivocal regarding a separate premolar field...."

These cases with their rotated maxillary P3-P4 units and perfectly formed premolar and molar crowns tentatively support the existence of a separate premolar morphogenic field, making the evidence slightly less equivocal.

ACKNOWLEDGEMENTS

I would like to acknowledge the following individuals for their assistance and access to the skeletal material examined in this study and for their permission to photograph the specimens presented in this report: Dr. Ian Tattersall, Dr. Kenneth M. Mowbray, and Gary Sawyer, American Museum of Natural History, New York, New York.

LITERATURE CITED

- Butler PM. 1937. Studies of the mammalian dentition. I. The teeth of *Centetes ecaudatus* and its allies. Proc Zool Soc Lond B107:103-132.
- Butler PM. 1939. Studies of the mammalian dentition. Differentiation of the post-canine dentition. Proc Zool Soc Lond B109:1-36.
- Dahlberg AA. 1945. The changing dentition of man. J Am Dent Assoc 32:676-690.
- Dahlberg AA. 1963. Analysis of the American Indian dentition. In: Brothwell DR, editor. Dental anthropology. London: Pergamon Press, p 149-178.
- Escobar V, Melnick M, Conneally PM. 1976. The inheritance of bilateral rotation of maxillary central incisors. Am J Phys Anthropol 45:109-116.
- Henderson AM, Greene DL. 1975. Dental field theory: an application to primate evolution. J Dent Res 54:344-350.
- Hillson S. 1996. Dental anthropology. New York: Cambridge University Press.
- Lui JL. 1980. Bilateral 180 degree rotation of maxillary second premolars: a case report. J Dent 8:257-259.
- Scott GR, Turner CG. 1997. The anthropology of modern human teeth: Dental morphology and its variation in recent human populations. New York: Cambridge University Press.
- Suarez BK, Williams BJ. 1973. Dental growth fields and premolar morphology. J Dent Res 52:632.
- Tay WM. 1968. Rotated maxillary second premolars two cases with 180 degree rotation. Br Dent J 124:326.
- Townsend GC, Brown T. 1981. Morphogenetic fields within the dentition. Aust Orthod J 7:3-12.
- van Nievelt AFH, Smith KK. 1997. Extreme bilateral molar rotation in *o* (Marsupialia: Didelphidae). Arch Oral Biol 42:587-591.
- Wood BA, Engleman CA. 1988. Analysis of the dental morphology of Plio-Pleistocene hominids. V.

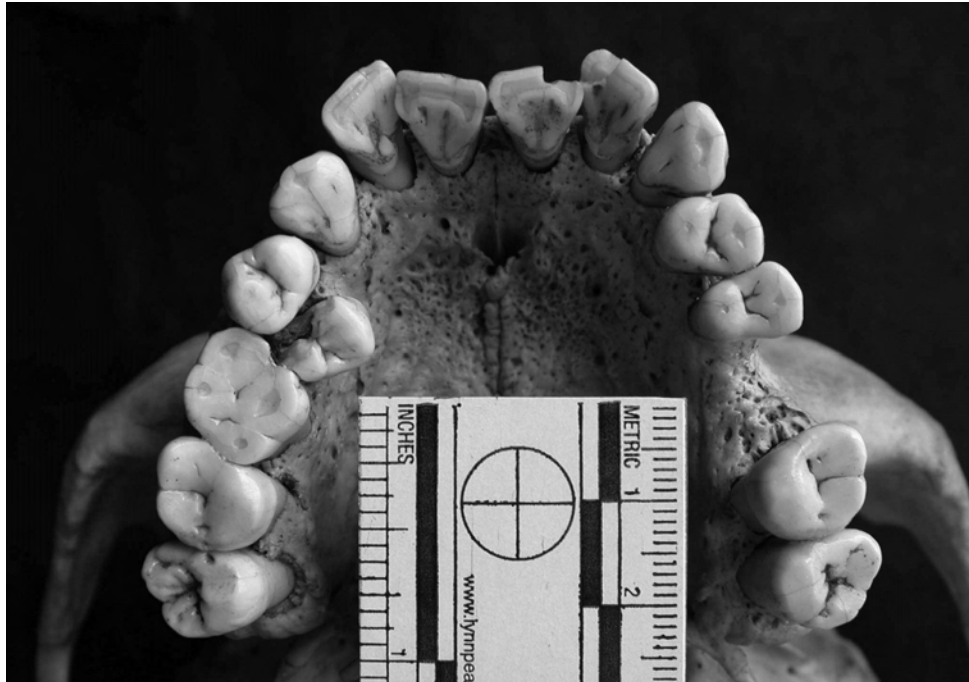

Fig. 3. Occlusal view of AMNH 99/8478 maxillary dentition.

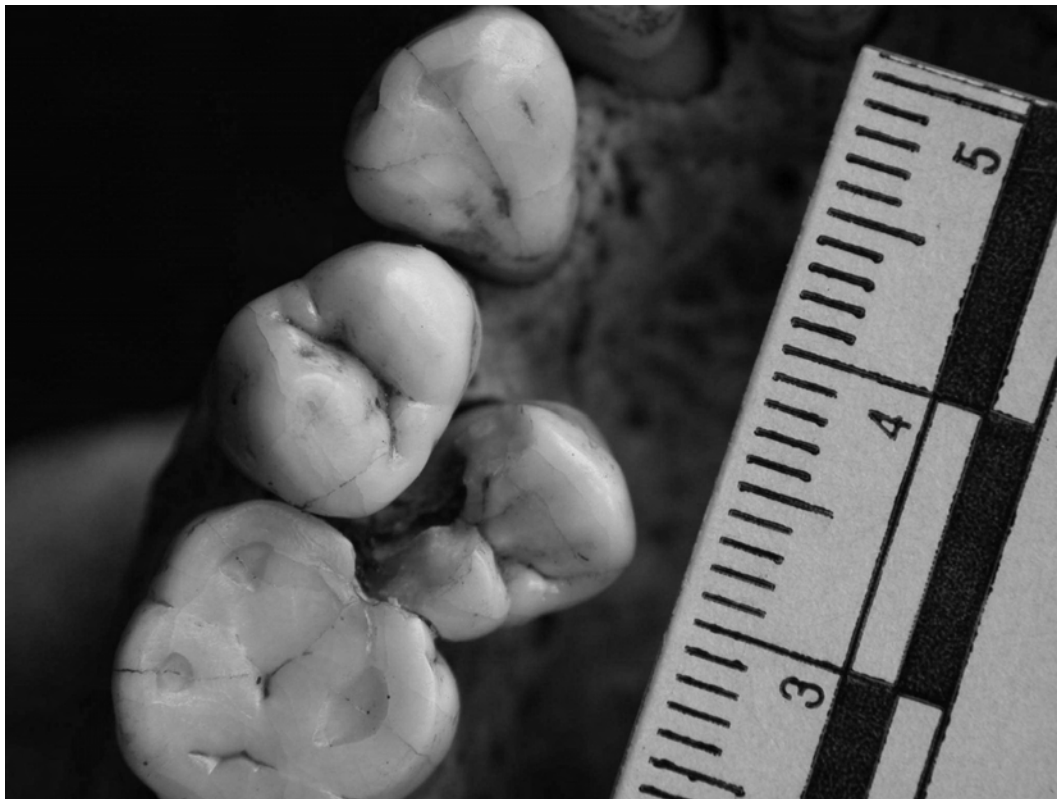


Fig. 4. Close-up view of right maxillary premolars of AMNH 99/8478.

Maxillary postcanine tooth morphology. *Journal of Anatomy* 161:1-35.
Wood BA, Abbott SA, Uytterschaur H. 1988. Analysis of

the dental morphology of Plio-Pleistocene hominids. IV. Mandibular postcanine root morphology. *J Anat* 156:107-139.

Commentary: Rotated Premolars

Edward F. Harris*

Department of Orthodontics and Department of Pediatric Dentistry, University of Tennessee, Memphis

Dr. Stefan's interesting description of two archeological cases with severely malposed premolars (*Dental Anthropology* 2006;19(3):70-73) prompted me to review two comparable cases I have encountered. I present these here in hopes that their description will stimulate discussion from the readership.

CASE 1

Figure 1 shows an occlusal view of the mandibular dental arch of a 24-year-old American black male. All 16 permanent mandibular teeth are erupted into functional occlusion, and, as shown in this figure, there is appreciable anterior dental crowding. The notable feature, of course, is the buccolingual juxtaposition of the left first and second premolars, where the second premolar is erupted ectopically to the lingual (with ~40° distolingual rotation) and the first premolar is rotated with the lingual aspect ~40° to the mesial. The canine is ectopically positioned to the labial in the corresponding right quadrant, but the two right premolars are arranged normally in the midarch. There is good gingival height around both ectopic premolars, with normal crown-root ratios as viewed from radiographs. Premolar alignment is normal in the maxillary arch.

CASE 2

This is a 14-year-old American white girl. Figure 2 shows the buccal-lingual arrangement of her maxillary right premolars. The second premolar is displaced to the lingual with mesial rotation of the tooth's lingual aspect. The first premolar is deviated less transversely, but the lingual aspect is rotated ~80° to the lingual (lingual rotation of the second premolar is ~60°). Gingival contours are healthy around all teeth. Premolar arrangement is normal in the other three quadrants. All 32 permanent teeth are present on X-ray, though the third molars have not yet emerged.

PERSPECTIVE

It is tenuous to speculate on the etiology of these rotations and displacements just from examination of the completed dentition because several different factors may have been contributory. One possibility, of course, is that the premolars' tooth crypts formed in the

wrong positions and these teeth's erupted malpositions reflect this developmental anomaly. Figure 3 shows a panoramic radiograph of a young boy with such a problem. Instead of the premolar crypts being located in the root bifurcations of the primary molars, the crypts of both the first and second premolar are beneath (apical to) the primary first molar. In this boy, the same malposition occurs in all four quadrants rather than just one quadrant as seen in the four older cases presented by Dr. Stefan and myself.

Alternatively, the permanent first molar (that emerges well before the premolars) could be the culprit. If this molar's eruptive path were deflected to the mesial, it would have compromised the arch space available for normal premolar eruption. With inadequate space, the premolars would remain trapped within the bone, or would have erupted along whatever pathway of least resistance presented itself. One can speculate that compromised space forced the premolars into the odd positions seen in the cases presented here. This situation occasionally occurs in the maxilla because of the upper molar's normal mesial-occlusal eruptive trajectory (*e.g.*, van der Linden and Duterloo, 1976; Duterloo, 1991). It is much less common in the mandible because the lower molar normally has an essentially vertical path of eruption. Figure 4 shows the panoramic radiograph of a case where the maxillary first molars are mesially inclined and are actively lysing through the distal root of the primary second molars. In contrast, the mandibular first molars have erupted normally, distal to the primary second molars. Several clinicians have reported on the occlusal consequences of first-molar ectopia, notably in the maxilla (*e.g.*, Kuroi and Bjerklin, 1986; Bjerklin, 1994; Barberia-Leache *et al.*, 2005). The scenario would be that the early-erupting first molar erupts in to the space that should be held by the primary second molar, leading to this primary tooth's premature loss, and the space for the normal emergence of the premolar is compromised, leading to failure to erupt (impaction) or, conceivably as seen in

*Correspondence to: Edward F. Harris, Department of Orthodontics, University of Tennessee, Memphis, TN 38163.

E-mail: eharris@utmem.edu

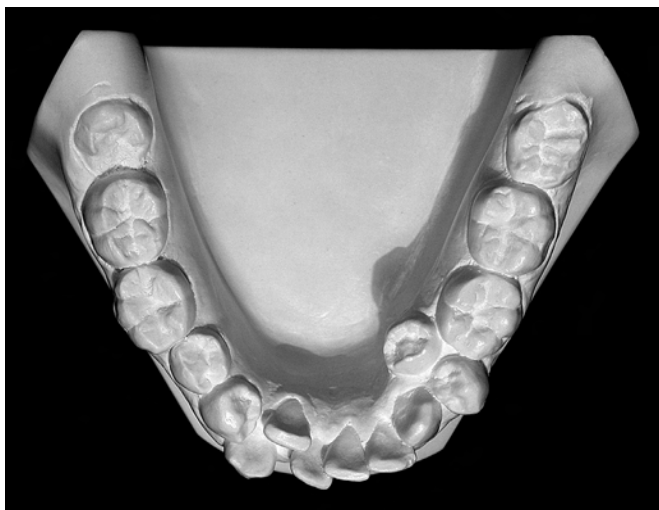
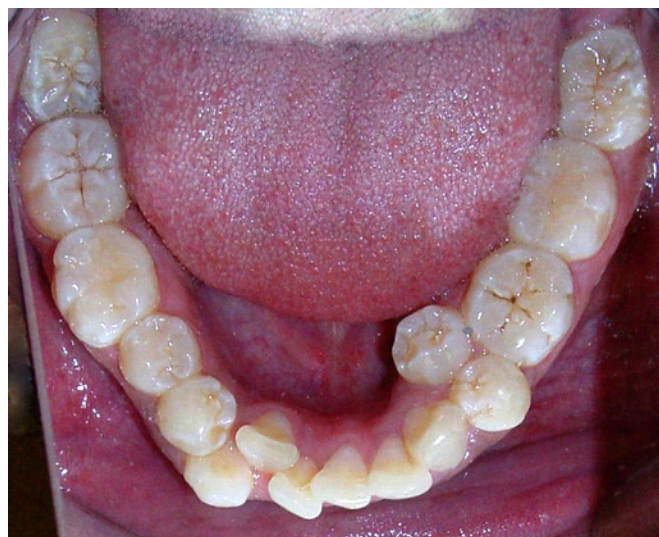
Fig. 1. Case of a young adult American black male with buccal-lingual juxtaposition of the mandibular left premolars. *Top*: Intraoral photograph of the mandibular arch, showing the ectopic premolars and appreciable anterior crowding. *Bottom*: Occlusal view of the same subject's dental cast.

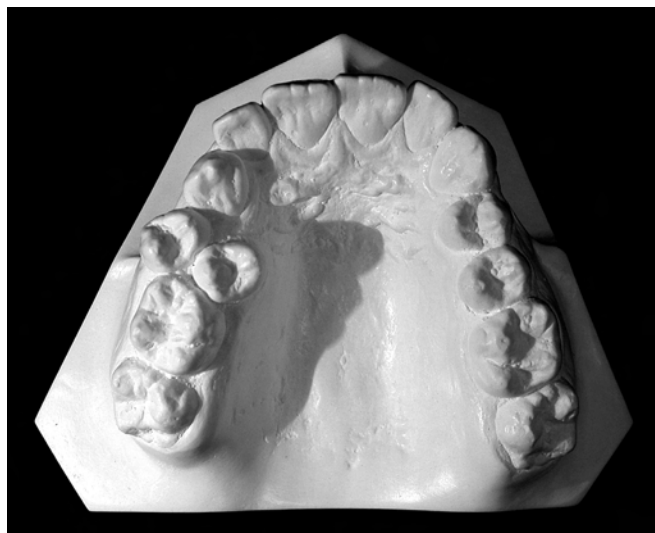
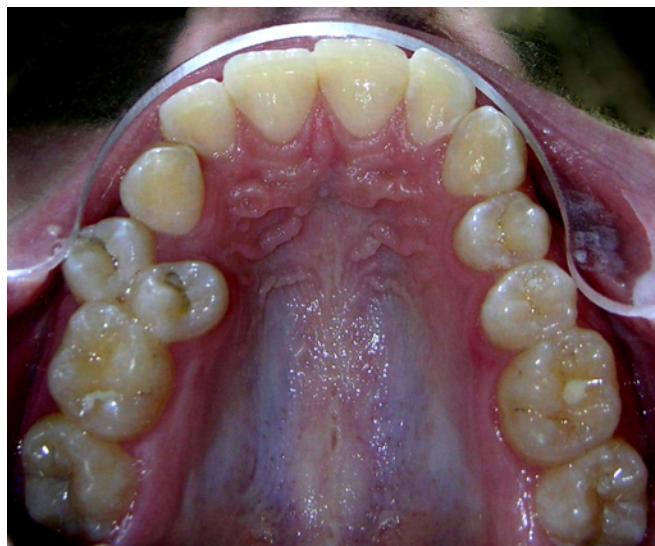


Fig. 2. Case of an adolescent American white female with buccal-lingual juxtaposition of the maxillary right premolars. *Top*: Intraoral photograph of the maxillary arch. Aside from the ectopic premolars in the right quadrant, there is little crowding. The absence of space mesial to the first or second molar on the right illustrates the effect of mesial drift. *Bottom*: Occlusal view of the same subject's dental cast.

Figures 1 and 2, ectopia of one or both premolars in a quadrant.

Another possibility is caries: Indeed, historically, caries was the greatest single cause of malocclusion (e.g., Weinberger, 1926). The two primary molars in a quadrant can be viewed as space holders for the later-emerging premolars. If one or both primary molar is lost prematurely because of caries, the permanent first molar will drift forward, diminishing the space available for normal eruption of one or both premolars.

An example of an impacted second premolar is shown in Figure 5; here the failure of eruption was due to caries and premature loss of the primary second molar, followed by mesial drift of the permanent first molar before the second premolar could erupt. Contemporary dentists have a variety of appliances that can be used to preserve the arch space of an extracted primary tooth (e.g., Ngan *et al.*, 1999; Choonara, 2005), but, of course, this was not an option in the past—when caries also was a more prevalent health problem.

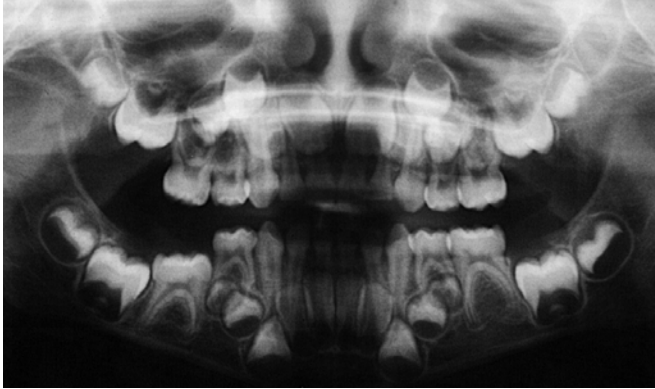

Fig. 3. Panoramic radiograph of young boy with ectopic development of the second premolars in each quadrant. Instead of the second premolar crypts forming in the bifurcation of the primary second molar's roots, as is normal, they are ectopically malpositioned apical to the primary first molars. Malpositions of the succedaneous tooth crypts is one possible cause of the maloccluded premolars seen in cases 1 and 2, though here—with all four quadrants involved—the problem probably is systemic rather than local.

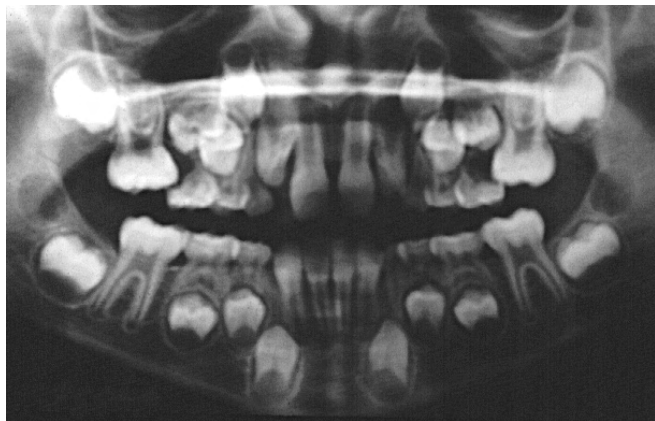


Fig. 4. Panoramic radiograph of a child in whom the maxillary permanent first molars have accentuated mesial crown tipping, with eruptive paths that have lysed the distal roots of the primary second molars. This leads to premature loss of the primary molars, followed by mesial drift of the permanent molars that, in turn, reduces space in the midarch that precludes normal eruption of the second premolars. Mesial inclination of the permanent first molars is appreciably more common in the maxilla.

A quick review of the literature shows that premature loss of a primary tooth affects the eruption tempo of its successor, but the effects reported are contradictory, some stating that premature loss accelerates eruption of the replacement tooth, others that loss delays eruption (reviewed, *e.g.*, by Ronnerman, 1977, Loevy, 1989). Fanning (1962), though often overlooked, was among the first to make sense of the situation, and my elaboration of her findings is this: When a primary tooth is lost at an early age, the supporting alveolar bone has plenty of time to heal and remodel (often atrophying to a narrow ridge) and the successor's root is too immature to initiate eruption (though the true "initiator" of eruption is poorly understood). Eruption of the successor is delayed in such cases, which increases the opportunity and extent of drift of teeth adjacent to the extraction site (*e.g.*, Ronnerman, 1977; Ronnerman and Thilander, 1978; Northway, 2000). In contrast, if the primary tooth is lost at an older age, the successor is more mature and closer to its normal eruption age, so the alveolar bone remains less remodeled and more cancellous (Boyne, 1995; Diedrich and Wehrbein, 1997; Hasler *et al.*, 1997), and eruption is hastened. When the successor erupts soon into the extraction space, there is little opportunity for drift of the adjacent teeth, thus enhancing chances of normal occlusal position.

Although uncommon, it is useful to mention pathological conditions that can retard exfoliation (of the primary tooth) and/or eruption (of the succedaneous tooth). An odontoma—a generally benign developmental hamartomatous lesion often coronal to an unerupted tooth—consists of tissues that resist tooth eruption as well as the normal migration

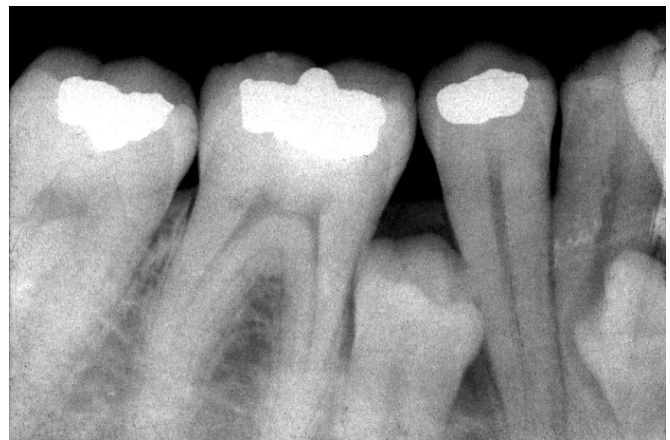

Fig. 5. Radiograph of an adolescent in whom the primary second molar exfoliated prematurely due to caries. Without dental intervention to hold the space, the permanent molars drifted mesially, resulting in the second premolar being impacted because its eruptive path was occluded by the earlier-emerging adjacent teeth.

of erupted teeth. Some odontomas form enamel and dentinal structures that look like miniature teeth (“toothlets”), but others leave no readily-discernible skeletal evidence of their existence. Morning (1980) reviewed tooth impactions secondary to odontomas (also see Amado Cuesta *et al.*, 2003; Tomizawa *et al.*, 2005). The case reported by Kupietzky and coworkers (2003) is relevant here because it details the ectopic displacement of a second molar consequent to an odontoma. In a similar vein, molecular biologists have discovered genes that influence tooth eruption, notably, mutant alleles that interfere with the normal lysis of bone ahead of an erupting tooth, which can lead to impaction (*e.g.*, Tiffée *et al.*, 1999; Nishino *et al.*, 2001; Ida-Yonemochi *et al.*, 2004).

The commonality of these various scenarios involves the similarity of developmental timing of the first and second premolars (and canine) in each quadrant. These three teeth erupt during what van der Linden and Duterloo (1976) term the “second transition” – roughly 10 to 12 years of age (Fig. 6). Hurme (1949, 1951, 1957) published syntheses of eruption studies, and his classic works are still among the most common citations on the subject. Hurme (1951) found that, modally, the second premolar erupts roughly 9 months later than the first premolar, though there is some inter-individual variation (Kent *et al.*, 1978; Smith and Garn, 1987; Diamanti and Townsend, 2003). Liversidge recently (2003) has collated the extensive literature from the 20th century. The data (based on various collection strategies and various statistical methods) show that the second premolars characteristically emerge later than the first, but, again, these averages hide the considerable variability among individuals. Inspection of the four cases reported by Dr. Stefan and myself show that, in each instance, the second premolar’s position is more aberrant than the first – and this is consistent with the later-emerging second premolar moving into a more-constrained space (because, statistically, the first premolar probably emerged slightly earlier and commandeered space for itself). It may be relevant too that in all four cases presented by Dr. Stefan and myself, the malposed premolars are restricted to one quadrant – suggesting that the etiology generally is anatomically localized rather than systemic.

Importantly, modal eruption ages can camouflage the variability in eruption sequences, though published reports of just the former are far more common. Sato and Parsons (1990) documented the appreciable variation seen in eruption sequences, particularly when the subjects can be followed longitudinally. The first premolar emerges ahead of the second (P1→P2) in most children (80% in maxilla; 96% in mandible), which agrees with the findings of Smith and Garn (1987) who, using cross-sectional data, found P1→P2 in about 90% of their children. Diamanti and Townsend (2003) also assessed data cross-sectionally, and found

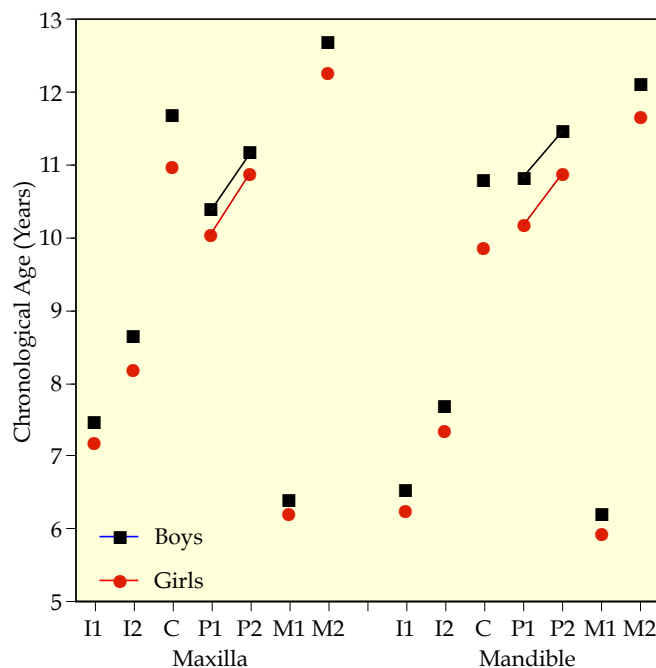


Fig. 6. Graph of median emergence ages in Caucasians (data from Hurme, 1951). Data are presented by sex, with gingival emergence being precocious in girls. The key issue is the similarity in emergence ages for the two premolars in a quadrant (*i.e.*, the pairs of symbols connected by lines); while the first premolar is characteristically developmentally advanced over the second, the times are so similar that these teeth are obliged to compete for limited arch space.

somewhat higher frequencies for P1→P2, about 97% in both arches. The relevant point here is that the data agree that the first premolar is quite likely to emerge before the second, thus putting P2 at greater risk for impaction or malposition – and this is what is seen in all four of the cases reviewed here.

These comments do not detract from Dr. Stefan’s presentation. Instead, they are meant to emphasize the dynamic sequence of events that, gone awry, can lead to the observed malplacements of later-forming teeth. Indeed, in addition to the broad criteria developed by Butler (1939) and Dahlberg (1945), a premolar field can be assessed by a variety of other measures, such as crown and root size and morphology, and similarities in formation, eruption, and emergence times and sequences.

ACKNOWLEDGEMENTS

I extend my thanks to Dr. Robert Turner and Dr. Jerome Burr who provided the orthodontic records of my case 1 and case 2, respectively. Dr. Betsy Barcroft provided the records for Figure 3, and Dr. Woodrow Powell provided the records for Figure 4.

LITERATURE CITED

- Amado Cuesta S, Gargallo Albiol J, Berini Aytes L, Gay Escoda C. 2003. Review of 61 cases of odontoma; presentation of an erupted complex odontoma. *Med Oral* 8:366-373.
- Barberia-Leache E, Suarez-Clua MC, Saavedra-Ontiveros D. 2005. Ectopic eruption of the maxillary first permanent molar: characteristics and occurrence in growing children. *Angle Orthod* 75:610-615.
- Bjerklin K. 1994. Ectopic eruption of the maxillary first permanent molar. An epidemiological, familial, aetiological and longitudinal clinical study. *Swed Dent J Suppl* 100:1-66.
- Boyne PJ. 1995. Use of HTR in tooth extraction sockets to maintain alveolar ridge height and increase concentration of alveolar bone matrix. *Gen Dent* 43:470-473.
- Butler PM. 1939. Studies of the mammalian dentition: differentiation of the post-canine dentition. *Proc Zool Soc Lond* B109:1-36.
- Choonara SA. 2005. Orthodontic space maintenance – a review of current concepts and methods. *SADJ* 60:113, 115-117.
- Dahlberg AA. 1945. The changing dentition of man. *J Am Dent Assoc* 32:676-690.
- Diamanti J, Townsend GC. 2003. New standards for permanent tooth emergence in Australian children. *Aust Dent J* 48:39-42.
- Diedrich P, Wehrbein H. 1997. Orthodontic retraction into recent and healed extraction sites: a histologic study. *J Orofac Orthop* 58:90-99.
- Duterloo HS. 1991. An atlas of dentition in childhood: orthodontic diagnosis and panoramic radiology. London: Wolfe Publishing Ltd.
- Fanning EA. 1962. Effect of extraction of deciduous molars on the formation and eruption of their successors. *Angle Orthod* 32:44-53.
- Hasler R, Schmid G, Ingervall B, Gebauer U. 1997. A clinical comparison of the rate of maxillary canine retraction into healed and recent extraction sites – a pilot study. *Eur J Orthod* 19:711-719.
- Hurme VO. 1949. Ranges of normalcy in the eruption of permanent teeth. *J Dent Child* 16:11-15.
- Hurme VO. 1951. Standards of variation in the eruption of the first six permanent teeth. *Child Devel* 37:800-803.
- Hurme VO. 1957. The human dentition in forensic medicine: symposium. *J Forensic Sci* 2:377-388.
- Ida-Yonemochi H, Ishibashi O, Sakai H, Saku T. 2004. Recruitment of osteoclasts in the mandible of osteopetrotic (op/op) mice. *Eur J Oral Sci* 112:148-155.
- Kent RL Jr, Reed RB, Moorrees CF. 1978. Associations in emergence age among permanent teeth. *Am J Phys Anthropol* 48:131-142.
- Kupietzky A, Flaitz CM, Zeltser R. 2003. Eruption of a severely displaced second permanent molar following surgical removal of an odontoma. *Pediatr Dent* 25:378-382.
- Kurol J, Bjerklin K. 1986. Ectopic eruption of maxillary first permanent molars: a review. *ASDC J Dent Child* 53:209-214.
- van der Linden FPGM, Duterloo HS. 1976. Development of the human dentition: an atlas. Hagerstown, MD: Harper and Row, Publishers.
- Liversidge H. 2003. Variation in modern human dental development. In: Thompson JL, Krovitz GE, Nelson AJ, eds. *Patterns of growth and development in the genus Homo*. Cambridge: Cambridge University Press, p 73-113.
- Loevy HT. 1989. The effect of primary tooth extraction on the eruption of succedaneous premolars. *J Am Dent Assoc* 118:715-718.
- Morning P. 1980. Impacted teeth in relation to odontomas. *Int J Oral Surg* 9:81-91.
- Ngan P, Alkire RG, Fields H Jr. 1999. Management of space problems in the primary and mixed dentitions. *J Am Dent Assoc* 130:1330-1339.
- Nishino I, Amizuka N, Ozawa H. 2001. Histochemical examination of osteoblastic activity in op/op mice with or without injection of recombinant M-CSF. *J Bone Miner Metab* 19:267-276.
- Northway WM. 2000. The not-so-harmless maxillary primary first molar extraction. *J Am Dent Assoc* 131:1711-1720.
- Ronnerman A. 1977. The effect of early loss of primary molars on tooth eruption and space conditions: a longitudinal study. *Acta Odontol Scand* 35:229-239.
- Ronnerman A, Thilander B. 1978. Facial and dental arch morphology in children with and without early loss of deciduous molars. *Am J Orthod* 73:47-58.
- Sato S, Parsons P. 1990. Eruption of permanent teeth: a color atlas. St Louis: Ishiyaku EuroAmerica, Inc.
- Smith BH, Garn SM. 1987. Polymorphisms in eruption sequence of permanent teeth in American children. *Am J Phys Anthropol* 74:289-303.
- Tiffée JC, Xing L, Nilsson S, Boyce BF. 1999. Dental abnormalities associated with failure of tooth eruption in src knockout and op/op mice. *Calcif Tissue Int* 65:53-58.
- Tomizawa M, Otsuka Y, Noda T. 2005. Clinical observations of odontomas in Japanese children: 39 cases including one recurrent case. *Int J Paediatr Dent* 15:37-43.
- Weinberger BW. 1926. *Orthodontics: an historical review of its origin and evolution*. St. Louis: CV Mosby Company.

A Byzantine Cranium from Jordan: A Case Study in Dental Anthropology

Abdulla Al-Shorman*

Department of Anthropology, Yarmouk University, Irbid-Jordan

ABSTRACT: This study describes a Byzantine cranium from an archaeological site in Jordan (Khirbit Yajuz). This case study illustrates severity of the multiple dental pathologies encountered and speculates on the cause of death. The 21-years-old female of this study suffered multiple dental abscesses, where the accumulated pus

reached the nasal cavity and the maxillary sinuses through a large fistula, probably causing septicemia that may have caused her early death. This case was selected from among similar cases from the site, and it illustrates an extreme, progressive state of caries and the absence of dental hygiene. *Dental Anthropology* 2006;19(3):79-82.

The study of the total collection of the human teeth from the archaeological site of Khirbit Yajuz has revealed striking results, notably conspicuous oblique dental wear on the first lower molars, premortem and perimortem tooth loss, dental abscesses in the maxilla, and progressive periodontal disease (Al-Shorman, 2003). The frequency of dental caries among the recovered skeletons ($n = 120$ individuals) is 13.3%, which is within the range of the other Byzantine sites in the region (Smith *et al.*, 1992; Williams *et al.*, 2004). These and other archaeological results suggest a population of low social status whose primary occupation was weaving (Al-Shorman and Khalil, 2006). In the upper jaw, most of the sites of tooth decay had developed into dental abscesses. In contrast, the low frequency of caries and the absence of dental abscesses in the lower jaw might have been triggered by the use of teeth as tools (Al-Shorman, 2003) that frequently polished the occlusal tooth surface, thereby removing sticky food particles and reducing depths of the fissures. In other words, the rate of dental wear was high enough to inhibit the development of dental caries on the occlusal surfaces of teeth (Powell, 1985). The frequency of dental abscesses among the Byzantine people of Khirbit Yajuz was extraordinarily high compared to similar sites; most of the investigated carious lesions had periapical abscesses.

A periapical abscess develops when the area surrounding the tip of the root is invaded by bacteria; fluids and dead bacteria accumulate in the periapical region, forming a pocket as part of the phagocytic defense process (Scott and Turner, 1988). Abscesses develop as the fluids break through the alveolar bone. An untreated case may develop a fistula either on the buccal or the lingual side (Alexandersen, 1967). A periapical abscess typically is the result of pulp exposure due to rapid attrition, caries, trauma, or periodontal disease (Hillson, 1996); all of these factors

were present among the Yajuz people. The present study presents one of the progressive cases of acute periapical abscesses and periodontal disease. This analysis also extracted the demographic variables of age and sex based on morphology of the cranium and development of the teeth. Dealing with the case from a forensic perspective, the study elucidates the probable cause of death.

MATERIALS AND METHODS

The study deals with the remains of one individual represented by a cranium that is dated to the Byzantine period, *ca.* 5th-8th century AD (Khalil, 1998, 2001). This cranium was visually assessed for the presence of periapical abscesses, caries, dental wear, and periodontal disease. The sex was estimated after Ascádi and Nemeskéri (1970), aging after Ubelaker (1989), wear according to Smith (1984), and abscesses and caries after Buikstra and Ubelaker (1994).

RESULTS AND DISCUSSION

The supraorbital margins are very sharp with only minor prominence of Glabella, indicating that the specimen was female. The third right upper molar is not in complete occlusion; it is below the level of the adjacent right second molar. This situation suggests an age of about 21 years (Ubelaker, 1989).

The maxilla retained five teeth, namely the right canine, right first premolar, right second molar, right third molar, and left first premolar. The other teeth were lost before death (premortem) or around death (perimortem).

*Correspondence to: Abdulla Al-Shorman, Department of Anthropology, Faculty of Archaeology and Anthropology, Yarmouk University, Irbid-Jordan
E-mail: alshorman@yu.edu.jo

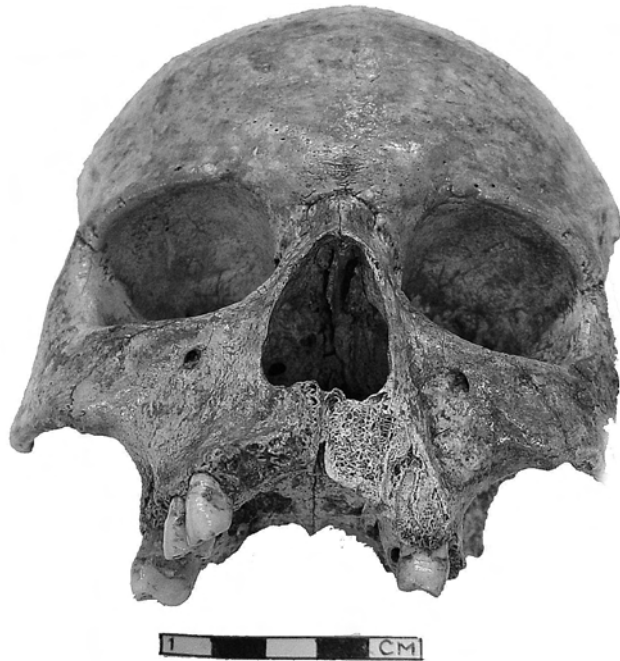

Fig. 1. An anterior view of the cranium. Photographed by Y. Al-Zou'bi.

The teeth that are present in occlusion exhibit minor dental wear, suggesting that the woman had a less abrasive diet and/or the teeth did not have enough time to be abraded because she died at a young age. The second right molar possesses two large caries, one on the mesial and the other on the distal cervical

TABLE 1. Maxillary tooth inventory

Tooth type	Side	Occlusion
First incisor	Right	Premortem loss
Second incisor*	Right	Perimortem loss
Canine	Right	Complete occlusion
First premolar	Right	Complete occlusion
Second premolar*	Right	Perimortem loss
First molar*	Right	Perimortem loss
Second molar	Right	In full occlusion
Third molar	Right	Below full occlusion
First incisor	Left	Postmortem loss
Second incisor	Left	Postmortem loss
Canine	Left	Postmortem loss
First premolar	Left	Postmortem loss
Second premolar	Left	In full occlusion
First molar	Left	Premortem loss
Second molar*	Left	Perimortem loss
Third molar*	Left	Perimortem loss

*Tooth exhibits a periapical abscess.

margin of the crown. The left second premolar also has a moderate lingual surface caries. Periodontal disease is prominent along the tooth arcade, with significant horizontal alveolar bone loss.

Five teeth exhibit periapical abscesses in advanced stages (Table 1). The most noticeable and advanced

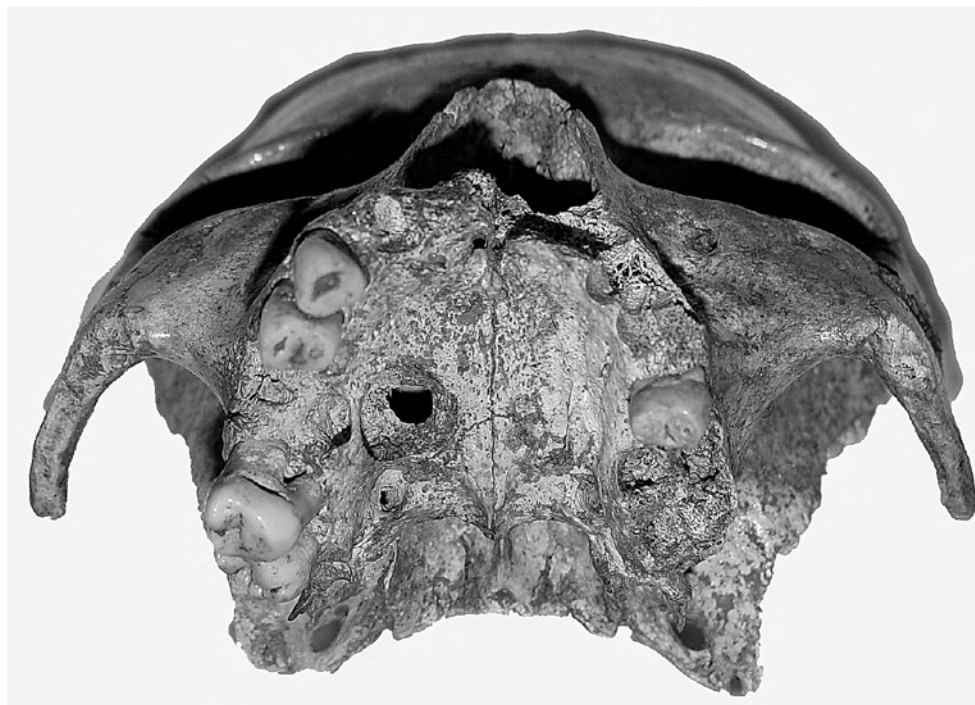


Fig. 2. Inferior view of the cranium showing the abscesses, dental caries and dental wear. Photographed by Y. Al-Zou'bi.



Fig. 3. Right lateral view showing bone destruction due to periodontal disease. Also note the buccal alveolar perforation and the lacrimal bone destruction. Photographed by Y. Al-Zou'bi.

one is the right first molar; perforations are present on the buccal and lingual sides of the alveolus. The pus accumulation was so destructive that the surrounding alveolar bone was resorbed for 8 mm above the buccal alveolar line. This resorption also exposed two-thirds of the adjacent second molar root. The amount of pus accumulation was certainly substantial: where it first formed a cyst in the palatine bone and then perforated the hard and soft palates, the fistula is about 3 mm in diameter. The pus seems to have accumulated in the nasal cavity; it is conceivable that the accumulated pus was running out of the individual's nose and mouth before death. The pus had also resorbed the nasal wall of the right maxillary sinus and the medial wall of the right orbit (the lacrimal bone). Edges of the perforation

of the lacrimal bone are smooth and almost oval in shape.

The presumed large amount of pus in the nasal cavity and the maxillary sinuses might have been absorbed by the epithelial tissues lining them. The pus probably infiltrated the blood stream causing septicemia. Since the person died during the active stage of the disease, septicemia is the probable cause of her death. The progress of the disease was from the root of the first molar to the palatine bone, followed by the nasal cavity, and then involvement of the maxillary sinus. Finally, the orbit was involved, all of which took a considerable amount of time, probably weeks. This extensive invasion stresses the woman's physiological ability to tolerate and cope with the disease, especially in the absence of medical intervention.

CONCLUSION

The multiple dental pathologies in this case involve a clear-cut situation of poor dental hygiene in the presence of a rich carbohydrate diet. Comparable multiple pathologies were common among the people of Khirbit Yajuz, especially among skeletal remains of the low social classes. Our case is from the Yajuz people; the woman belonged to a low social class and probably died of septicemia at around 21 years of age.

LITERATURE CITED

- Ascádi G, Nemeskéri J. 1970. History of human life span and mortality. Budapest: Akadémiai Kaidó.
- Alexandersen V. 1967. The pathology of jaws and temporomandibular joints. In: Brothwell D, Sandison A, editors. Diseases in antiquity. Springfield: Charles C Thomas, p 551-595.
- Al-Shorman A. 2003. A Byzantine tomb from Khirbit Yajuz, Jordan. *J Paleopathology* 15:177-185.
- Al-Shorman A, Khalil L. 2006. The evidence of weaving at Khirbit Yajuz in Jordan using dental microwear. *Int J Dental Anthropol* 8:1-9.
- Buikstra J, Ubelaker D. 1994. Standards for data collection from human skeletal remains. Arkansas Archaeological Survey Research Series. Fayetteville: Arkansas Archaeological Survey Research Series.
- Hillson S. 1996. Dental anthropology. Cambridge: Cambridge University Press.
- Khalil L. 1998. University of Jordan's excavations at Khirbit Yajuz. *Annual of the Department of Antiquities Jordan* 42:457-472.
- Khalil L. 2001. Glass vessels from and miniature jugs from Khirbit Yajuz cemetery, Jordan. *Levant* 33:127-138.
- Powell M. 1985. The analysis of dental wear and caries for dietary reconstruction. In: Gilbert R Jr, Mielke J, editors. The analysis of prehistoric diets. Orlando: Academic Press, p 307-383.
- Scott GR, Turner CG II. 1988. Dental anthropology. *Ann*

- Rev Anthropol 17:99-126.
- Smith B. 1984. Patterns of molar wear in hunter-gatherers and agriculturalists. *Am J Phys Anthropol* 63:39-56.
- Smith P, Horowitz L, Dujovny L. 1992. The human remains from area H. In: de Groot A, Ariel D, editors. *Excavations at the city of David 1978-1985*. Vol. III. Stratigraphical, environmental, and other reports. QEDM Monographs of the Institute of Archaeology, 33. Jerusalem, Israel: The Institute of Archaeology, The Hebrew University of Jerusalem.
- Ubelaker J. 1989. *Human skeletal remains*, 2nd ed. Washington, DC: Taraxacum Press.
- Williams K, El-Najjar M, Rose J, Al-Koufahi H, King M, Al-Awad F. 2004. Skeletal biology. In: Rose J, Burke D, editors. *A late Byzantine site in North Jordan*. Irbid, Jordan: Yarmouk University Press, p 146-180.

Brief Communication: Occurrence of an Eighth Cusp on Primary Second Mandibular Molars of a Contemporary Argentinean Child

Carlos David Rodríguez Florez^{1*}, Gabriel Mario Fonseca², and Maria Teresa de Villalba³

¹Cátedra de Antropología Biológica y Cultural, Facultad de Ciencias Exactas, Físicas y Naturales, ²Cátedra de Anatomía Patológica B, Facultad de Odontología, and ³Cátedra de Ortodoncia, Facultad de Odontología - Universidad Nacional de Córdoba, Argentina.

ABSTRACT: The presence and asymmetry of an eighth cusp observed on the primary second mandibular molars of an Argentinean boy is described. *Dental Anthropology* 2006;19(3):83-85.

Dental morphology trait expressions have been used in anthropology and forensic sciences for determination of biological and geographical affiliations. Variations in morphology of crowns may be manifest in the primary and/or permanent dentitions. Dental variation is heritable, is caused by multiple genes, and is little influenced by environmental factors. Traditionally, three, four, five, six or seven cusps, specifically the protoconid, metaconid, hypoconid, entoconid, hypoconulid, entoconulid and metaconulid, have been reported in morphological descriptions of lower molars for various human groups (Axelsson and Kirverskari, 1979; DeVoto and Perroto, 1972; Hanihara, 1967; Harris and Bailit, 1980; Morris, 1965; Sciulli, 1977; Schroeder *et al.*, 1983; Scott and Turner 1997; Suzuki and Sakai, 1973). This brief communication reports on the presence and asymmetry of a possible eighth cusp on mandibular primary second molars of a contemporary Argentinean boy.

MATERIALS AND METHODS

The teeth of a racially mixed boy five years of age from Cordoba City, Argentina, were examined in situ and on a plaster cast. An unusually shaped accessory occlusal cusp was observed on both the left and right mandibular primary second molars. Size of this eighth cusp was measured with sliding calipers. This case report is part of an anthropological study carried out on material provided by the Departamento de Ortodoncia, Facultad de Odontología, Universidad Nacional de Cordoba, Argentina.

RESULTS

Figures 1 and 2 illustrate the presence and bilateral asymmetry observed on mandibular primary second molars. A small additional cusp occurs between hypoconulid and entoconulid cusps. The anomalous cusp is larger on the right molar (diameter: 0.245 mm) than the left (diameter: 0.165 mm).

DISCUSSION

This accessory, eighth cusp has been not reported previously. This rare variant on anomalous lower primary molars provides an interesting record of eighth cusp in human dental morphology. Bilateral presence and asymmetrical appearance of the eighth cusp suggest a possible factor of heritability in the expression of this infrequently human molar form. Brabant suggests that primary second mandibular molars with five cusps are most common. Six cusps are less frequent (2% to 30%), and the seven-cusp molar – with a cusp of Jørgensen (metaconulid) – is found in less than 10% of cases (Brabant, 1967). Kallay's (1966) classification

Grant Sponsor: Facultad de Odontología, Universidad Nacional de Córdoba, Argentina.

*Correspondence to: Carlos David Rodríguez Florez, Cátedra de Antropología Biológica y Cultural, Facultad de Ciencias Exactas, Físicas y Naturales - Universidad Nacional de Córdoba, Argentina.
E-mail: david@syllabapress.com

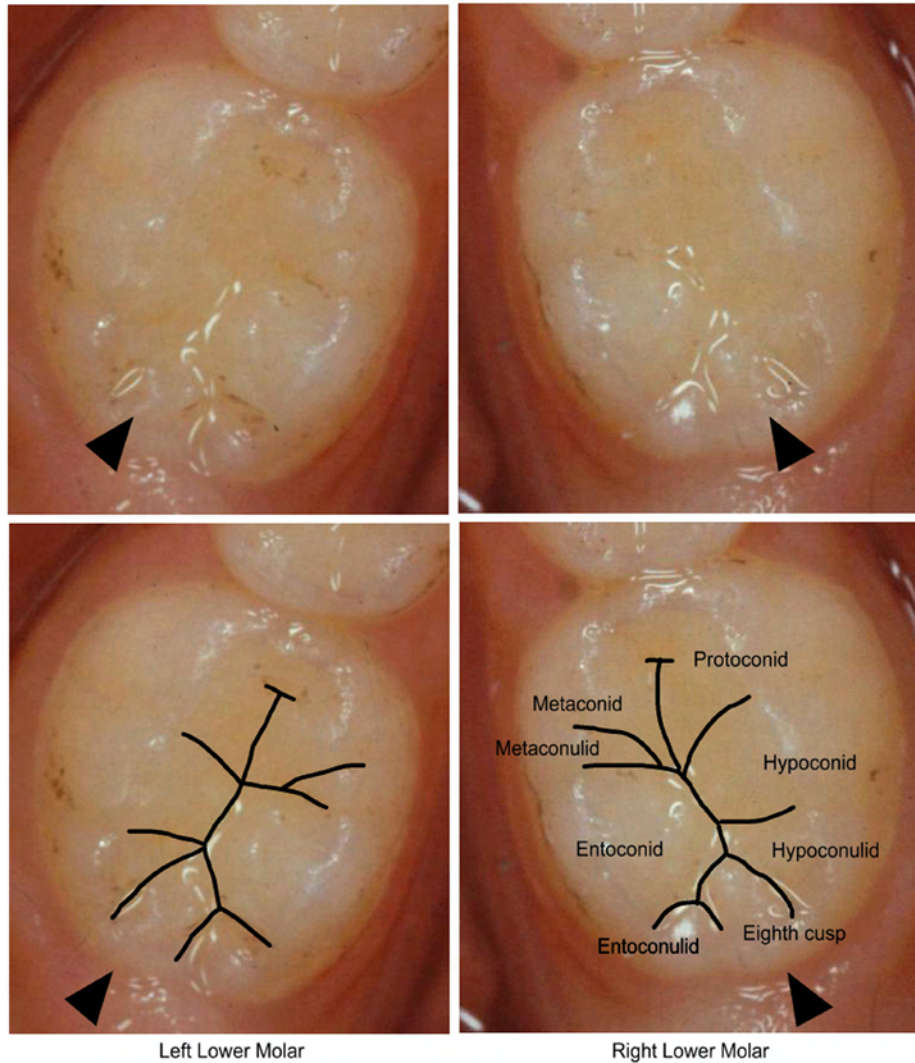


Fig. 1. Occlusal view of case (*in situ*).

could be used to label this eighth cusp, perhaps the *Protuberantio apulparis* sited in the distal occlusal area of primary second lower molars. As mentioned by Brothwell (1967), the phenomenon of increasing world contact, immigration, and interbreeding between previously more isolated communities can produce new forms that enrich the variation observed in the human dentition.

LITERATURE CITED

- Axelsson G, Kirveskari P. 1979. Sixth and seventh cusp on lower molar teeth of Icelanders. *Am J Phys Anthropol* 51:79-82.
- Brabant H. 1967. Comparison of the characteristics and anomalies of the deciduous and the permanent dentition. *J Dent Res* 46:897-902.
- Brothwell DR. 1967. Some problems and objectives related to the study of dental variation in human populations. *J Dent Res* 46:938-941.
- DeVoto FCH, Perroto BM. 1972. Groove pattern and cusp number of mandibular molars from Tastiian Indians. *J Dent Res* 51:205.
- Hanihara K. 1967. Racial characteristics in the dentition. *J Dent Res* 46:923-926.
- Harris EF, Bailit HL. 1980. The metaconule: a morphologic and familial analysis of a molar cusp in humans. *Am J Phys Anthropol* 53:349-358.
- Kallay J. 1966. Extra cusp formation in the human dentition. *J Dent Res* 45:1381-1394.
- Morris DH. 1965. The anthropological utility of dental morphology. Ph.D. dissertation, Department of Anthropology, University of Arizona. Tucson, AZ.
- Sciulli PW. 1977. A descriptive and comparative study of the deciduous dentition of prehistoric Ohio Valley Amerindians. *Am J Phys Anthropol* 46:71-80.

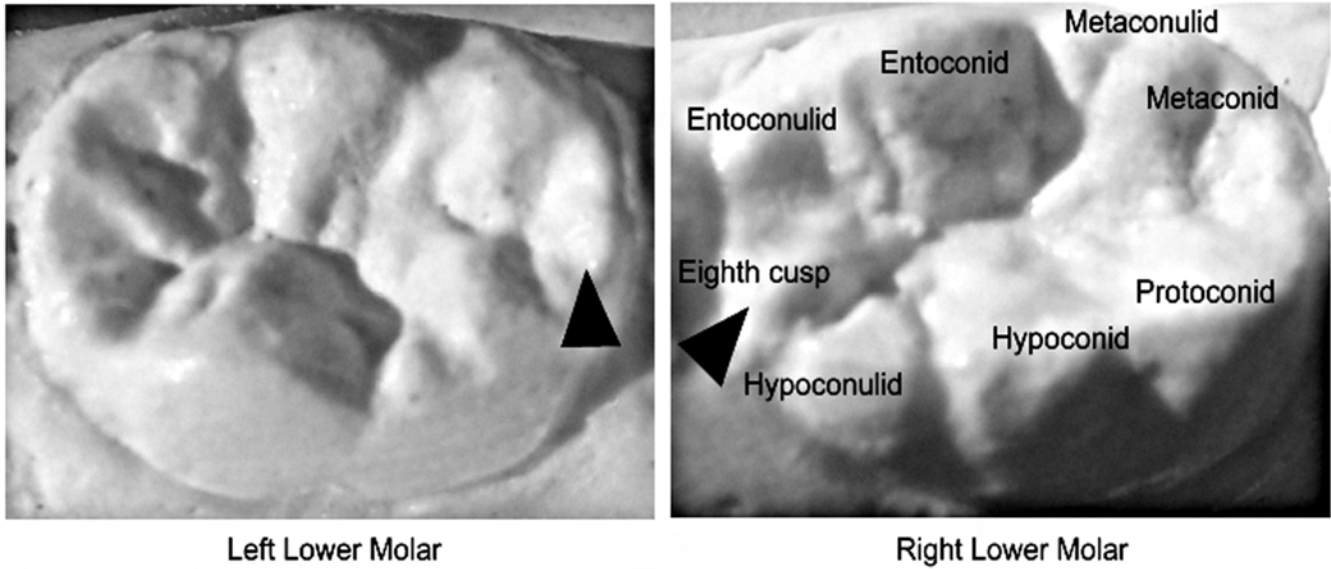


Fig. 2. Occlusal view of the mandibular second molars as seen on the plaster cast.

- Schroeder K, Zacherl W, Paulson R, Gaston P, Sciulli PW. 1983. Cusp tip abnormalities in the deciduous and permanent dentitions. *J Dent Res* 62:224.
- Scott GR, Turner II CG. 1997. *The anthropology of modern human teeth*. Cambridge: Cambridge University Press.
- Suzuki M, Sakai T. 1973. Occlusal surface pattern of the lower molars and the second deciduous molar among the living Polynesians. *Am J Phys Anthropol* 39:305-315.



RESEARCH COMPETITION in DENTAL ANTHROPOLOGY

THE ALBERT A. DAHLBERG PRIZE

The Albert A. Dahlberg Prize is awarded annually to the best student paper submitted to the *Dental Anthropology Association (DAA)*. Dr. Dahlberg was a professor at the University of Chicago, one of the founders of the International Dental Morphology Symposia, and among the first modern researchers to describe variations in dental morphology and to write cogently about these variations, their origins, and importance. The prize is endowed from the Albert A. Dahlberg Fund established through generous gifts by Mrs. Thelma Dahlberg and other members of the Association.

Papers may be on any subject related to dental anthropology. The recipient of the Albert A. Dahlberg Student prize will receive a cash award of \$200.00, a one-year membership in the Dental Anthropology Association, and an invitation to publish the paper in *Dental Anthropology*, the journal of the Association.

Students should submit three copies of their papers in English to the President of the DAA. Manuscripts must be received by January 31, 2007. The format must follow that of *Dental Anthropology*, which is similar to the style of the *American Journal of Physical Anthropology*. The Style Guide for Authors is available at the web site for the AJPA (<http://www.physanth.org>) or by e-mail from the AJPA editor (ajpa@osu.edu).

The manuscript should be accompanied by a letter from the student's supervisor indicating that the individual is the primary author of the research and the paper. Multiple authorship is acceptable, but the majority of the research and writing must be the obvious work of the student applying for the prize. Send enquiries and submissions to the President of the DAA:

Professor Simon Hillson
Institute of Archaeology
University College London
31-34 Gordon Square
London WC1H 0PY
United Kingdom
e-mail: simon.hillson@ucl.ac.uk

The DAA reserves the right to select more than one paper, in which case the prize money will be shared equally among the winners. They also reserve the right to not select a winner in a particular year.

The winner of the Albert A. Dahlberg Student Prize will be announced at the Annual Meeting of the DAA, which is held in conjunction with the annual meeting of the American Association of Physical Anthropologists. In 2007, the meeting will be held in Philadelphia, Pennsylvania, March 27 - April 1.

The Relative Sexual Dimorphism of Human Incisor Crown and Root Dimensions

Edward F. Harris* and W. Max Couch, Jr.

Department of Orthodontics, University of Tennessee, Memphis, TN 38163

ABSTRACT: Teeth are unusual structures in that their dimensions are sexually dimorphic even though they form early in life, several years before steroid-mediated adolescence. These size differences make teeth attractive as indicators of a specimen's sex. Alternatively, the magnitude of sexual dimorphism in humans is low, so there is considerable overlap in sizes between the two sexes. Prior studies suggest that tooth root dimensions are more dimorphic than crown dimensions, so roots would be more useful for sex determination. To explore this, we measured the four incisor tooth types from standardized periapical radiographs in a sample

($n = 148$) of living American white adolescents. Root lengths are somewhat more dimorphic than crown sizes in this sample (*ca.* 6% vs. 2%), and this translates into somewhat higher discriminatory power. The hindrance, however, is that all crown and root sizes are positively intercorrelated, so there is effectively just one dentition-wide axis of "tooth size" variation. Statistically, at least for these incisor tooth types, there is no added discriminatory power in the crown sizes once root dimensions have been accounted for, though the addition of data from other tooth types might improve discrimination somewhat. *Dental Anthropology* 2006;19(3):87-95.

Human tooth crown dimensions exhibit little sexual dimorphism, which detracts for their usefulness for sex determination (Ditch and Rose, 1972; De Vito and Saunders, 1990). Garn *et al.* (1967) showed that sexual dimorphism in a sample of American whites is only on the order of 3-5%, making them substantially less dimorphic than any of the other higher primates (*e.g.*, Swindler, 2002; Koppe and Swindler, 2004). The canines characteristically are the most dimorphic (*ca.* 6%), notably their buccolingual widths.

Sexual dimorphism in tooth size is useful in forensic settings (Teschler-Nicola and Prossinger, 1998) and also in archeological settings when the more informative skeletal elements are immature or absent (Krogman and Iscan, 1986; Ubelaker, 1999). That sex differences occur at all in the primary and permanent teeth is of interest because they depend on hormonal differences that preferentially develop size and shape in one sex over the other well before the onset of steroid-mediated adolescence (Tanner *et al.*, 1959; Manning, 2002).

We have collected incisor crown and root dimensions from a contemporary sample of American whites, and the purpose of this paper is to assess the relative sexual discriminating effectiveness of these crown and root variables.

females). These were healthy, phenotypically normal teenagers (mean age 14 years). All of the teeth were caries-free, and none had been treated orthodontically, which typically reduces root length due to external apical root resorption (Brezniak and Wasserstein, 1993a,b). Subjects were old enough to ensure root apexification, which is completed for the incisors around 10 years of age (Harris and McKee, 1990). Radiographs had been taken by an experienced dentist using a long-cone paralleling technique. Teeth with rotations or angulations affecting tooth-to film orientations were omitted from analysis. Radiographs give a proper measure of crown height since the cemento-enamel junction is not obscured by the gingiva (*cf.* Rhee and Nahm, 2000).

Radiographs were digitized at 1,200 dpi and 256-greyscale. SigmaScan 5.0 (SPSS Inc., Chicago, IL) was used to obtain crown and root dimensions, which were corrected for magnification prior to statistical analysis. The screen image of each tooth was magnified several-fold, which enhances landmark location but does not affect the dimensions obtained. The tooth with better image quality and alignment was chosen from each left-right pair. If there was no difference, the tooth in the left quadrant was analyzed, so sample sizes are of individuals, not teeth.

MATERIALS AND METHODS

Incisor dimensions were obtained from standardized periapical radiographs using a computer assisted measurement system. Data were collected from 148 adolescent American white adolescents (57 males, 91

*Correspondence to: Edward F. Harris, Department of Orthodontics, University of Tennessee, Memphis, TN 38163.

E-mail: eharris@utm.edu

Full-mouth dental casts were taken along with the periapical radiographs, and we measured the maximum mesiodistal crown dimensions of the teeth using sliding calipers, which provide an absolute measure of tooth size as well an internal check of the radiographic method. Four dimensions are evaluated here, (1) mesiodistal crown width, (2) overall tooth length, (3) crown height, and (4) root length.

Overall tooth length was measured from the root apex coronally to the mediolateral midpoint of the tooth's incisal edge (Fig. 1). Root length—from the root apex to the cemento-enamel junction (CEJ)—is not an invariant distance because the CEJ undulates around the tooth's periphery (Zeisz and Nuckolls, 1949), with the CEJ higher (more occlusal) on the tooth's mesial and distal aspects than labially or lingually. We measured the straight-line distance from the root apex separately to the mesial and the distal margins of the CEJ. For the

present study, the average of these two distances was used as root length. This distance was subtracted on an individual basis from tooth length to yield crown height. In sum, tooth length equals crown height plus root length.

Sexual dimorphism was assessed statistically using factorial analysis of variance (Winer *et al.*, 1991) and stepwise multivariate discriminant functions analysis (Cooley and Lohnes, 1971). Principal components analysis (Gorsuch, 1983) was performed to evaluate the statistical associations among the variables. Statistics were calculated using the JMP software package (SAS Institute Inc., Cary, NC).

RESULTS

Tooth Dimensions

Of the four incisor tooth types, mesiodistal crown diameter of just the upper central incisor (U1) exhibits

TABLE 1. Descriptive incisor dimensions, by sex, and tests for sexual dimorphism¹

Tooth	n	Males			Females			% Sex Dimorphism	Adjusted r ² %	Analysis of Variance		
		\bar{x}	sd	sem	n	\bar{x}	sd			sem	F-ratio	P value
Crown Width												
U1	57	9.23	0.81	0.11	91	8.91	0.59	0.06	3.69	4.61	8.10	0.0051
U2	55	6.98	0.60	0.08	90	6.90	0.62	0.06	1.15	(-0.30)#	0.57	0.4497
L1	56	5.41	0.46	0.06	91	5.32	0.40	0.04	1.82	0.54	1.79	0.1828
L2	57	6.07	0.51	0.07	90	5.97	0.39	0.04	1.72	0.64	1.93	0.1666
Tooth Length												
U1	57	26.36	2.49	0.33	91	25.21	2.14	0.22	4.56	5.11	8.91	0.0033
U2	56	25.15	2.42	0.32	90	23.78	1.95	0.21	5.76	8.29	14.11	0.0002
L1	56	22.48	2.22	0.30	91	21.60	1.86	0.19	4.08	3.76	6.70	0.0106
L2	57	23.90	2.54	0.34	91	23.04	1.87	0.20	3.71	2.99	5.54	0.0199
Crown Height												
U1	57	8.40	1.00	0.13	91	8.24	0.86	0.09	1.93	0.04	1.06	0.3042
U2	56	7.45	0.86	0.11	90	7.14	0.69	0.07	4.31	3.10	5.64	0.0189
L1	56	7.05	1.01	0.14	91	7.14	0.86	0.09	-1.19	(-0.49)#	0.30	0.5874
L2	57	7.23	0.95	0.13	91	7.23	0.81	0.08	-0.01	(-0.69)#	0.00	0.9961
Root Length												
U1	57	17.95	1.98	0.26	91	16.96	1.86	0.20	5.84	5.45	9.47	0.0025
U2	56	17.70	1.99	0.27	90	16.64	1.75	0.18	6.38	6.70	11.41	0.0009
L1	56	15.43	1.70	0.23	91	14.47	1.38	0.14	6.68	8.34	14.29	0.0002
L2	57	16.67	1.96	0.26	91	15.81	1.39	0.15	5.41	5.55	9.64	0.0023
Crown-Root Ratio												
U1	57	0.47	0.07	0.01	91	0.49	0.07	0.01	-3.95	1.19	2.77	0.0981
U2	56	0.42	0.06	0.01	90	0.43	0.06	0.01	-2.14	(-0.09)#	0.86	0.3542
L1	56	0.46	0.07	0.01	91	0.50	0.06	0.01	-7.17	5.98	10.29	0.0016
L2	57	0.44	0.06	0.01	91	0.46	0.05	0.01	-4.80	3.20	5.86	0.0168

¹Tooth codes are maxillary central (U1) and lateral (U2) incisor and mandibular central (L1) and lateral (L2) incisor. Sexual dimorphism is calculated from the means, ((M-F)/F) times 100. Adjusted r² is the variation in the tooth dimension accounted for by sexual dimorphism (the independent variable) in the analysis of variance.

#The r² is close to zero, and the adjustment caused the estimate to be negative, though this has no statistical interpretation (and should be set to zero).

TABLE 2. Matrix of Pearson correlation coefficients for the 16 incisor dimensions studied¹

	U1 CW	U2 CW	L1 CW	L2 CW	U1 TL	U2 TL	L1 TL	L2 TL	U1 CH	U2 CH	L1 CH	L2 CH	U1 RL	U2 RL	L1 RL	L2 RL
U1 CW	1.00	0.55	0.62	0.58	0.35	0.32	0.43	0.44	0.45	0.35	0.35	0.39	0.21	0.23	0.35	0.36
U2 CW	0.55	1.00	0.52	0.54	0.27	0.34	0.19	0.22	0.29	0.38	0.23	0.32	0.19	0.23	0.11	0.11
L1 CW	0.62	0.52	1.00	0.68	0.27	0.23	0.48	0.44	0.41	0.31	0.48	0.42	0.13	0.14	0.34	0.34
L2 CW	0.58	0.54	0.68	1.00	0.21	0.18	0.38	0.38	0.31	0.26	0.44	0.43	0.11	0.11	0.23	0.27
U1 TL	0.35	0.27	0.27	0.21	1.00	0.67	0.51	0.51	0.56	0.38	0.26	0.33	0.93	0.62	0.51	0.49
U2 TL	0.32	0.34	0.23	0.18	0.67	1.00	0.54	0.53	0.35	0.51	0.23	0.32	0.64	0.94	0.56	0.51
L1 TL	0.43	0.19	0.48	0.38	0.51	0.54	1.00	0.88	0.36	0.26	0.67	0.59	0.45	0.51	0.90	0.82
L2 TL	0.44	0.22	0.44	0.38	0.51	0.53	0.88	1.00	0.35	0.32	0.62	0.67	0.45	0.48	0.78	0.93
U1 CH	0.45	0.29	0.41	0.31	0.56	0.35	0.36	0.35	1.00	0.48	0.46	0.44	0.21	0.21	0.19	0.22
U2 CH	0.35	0.38	0.31	0.26	0.38	0.51	0.26	0.32	0.48	1.00	0.32	0.38	0.24	0.18	0.15	0.22
L1 CH	0.35	0.23	0.48	0.44	0.26	0.23	0.67	0.62	0.46	0.32	1.00	0.77	0.10	0.13	0.28	0.40
L2 CH	0.39	0.32	0.42	0.43	0.33	0.32	0.59	0.67	0.44	0.38	0.77	1.00	0.19	0.22	0.31	0.35
U1 RL	0.21	0.19	0.13	0.11	0.93	0.64	0.45	0.45	0.21	0.24	0.10	0.19	1.00	0.63	0.51	0.48
U2 RL	0.23	0.23	0.14	0.11	0.62	0.94	0.51	0.48	0.21	0.18	0.13	0.22	0.63	1.00	0.58	0.50
L1 RL	0.35	0.11	0.34	0.23	0.51	0.56	0.90	0.78	0.19	0.15	0.28	0.31	0.51	0.58	1.00	0.82
L2 RL	0.36	0.11	0.34	0.27	0.49	0.51	0.82	0.93	0.22	0.22	0.40	0.35	0.48	0.50	0.82	1.00

¹Variable codes are crown width (CW), tooth length (TL), crown height (CH), and root length (RL). Sample size was 148 individuals for all correlations, so coefficients above 0.16 are statistically significant ($P < 0.05$; Rohlf and Sokal, 1981).

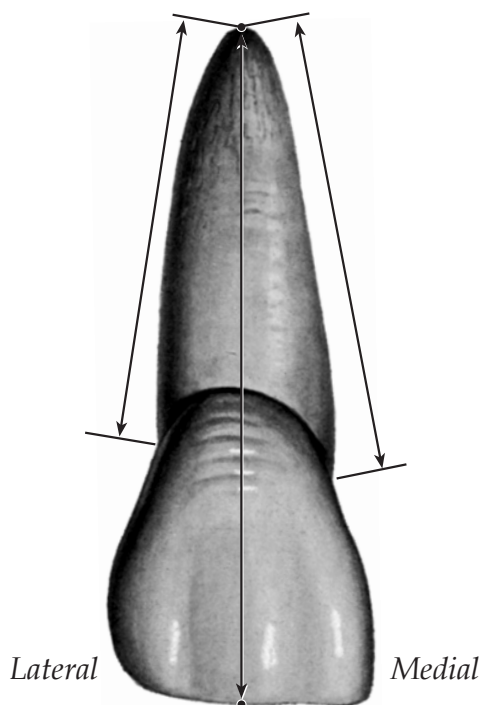


Fig. 1. Labial view of a maxillary right central incisor showing measurements of root length determined separately on the medial and lateral aspects (from root apex to CEJ) and tooth length (from root apex to midpoint of incisal edge). Crown height was operationalized as tooth length minus root length (*i.e.*, average of medial and lateral distances), which yields a longer root length (and shorter crown height) than if the labial or lingual level of the CEJ had been used.

TABLE 3. Results of principal components analysis on 16 incisor dimensions, without rotation

Tooth	Eigenvectors			
	I	II	III	IV
Crown Width				
U1	0.061	0.044	0.038	0.177
U2	0.038	-0.019	-0.010	0.198
L1	0.034	0.048	0.029	0.112
L2	0.028	0.042	0.029	0.116
Tooth Length				
U1	0.418	-0.405	0.497	0.108
U2	0.382	-0.276	-0.535	0.248
L1	0.367	0.409	0.027	0.000
L2	0.371	0.423	0.073	0.065
Crown Height				
U1	0.083	-0.015	0.144	0.427
U2	0.063	-0.026	0.006	0.313
L1	0.087	0.182	0.094	0.361
L2	0.086	0.121	0.063	0.330
Root Length				
U1	0.335	-0.390	0.353	-0.320
U2	0.319	-0.250	-0.542	-0.065
L1	0.280	0.228	-0.067	-0.361
L2	0.285	0.302	0.010	-0.265
Eigenvalue	21.164	5.475	2.785	1.836
Percent	61.847	16.000	8.138	5.365
Cumulative				
Percent	61.847	77.847	85.986	91.351

TABLE 4. Descriptive statistics for the principal components scores and tests for sexual dimorphism¹

Axis	Males				Females				Adjusted r ² %	Analysis of Variance	
	n	\bar{x}	sd	sem	n	\bar{x}	sd	sem		F-ratio	P value
PC I	54	1.582	4.886	0.665	89	-0.960	4.160	0.441	6.563	10.97	0.0012
PC II	54	-0.136	2.537	0.345	89	0.082	2.223	0.236	(-0.503) [#]	0.29	0.5912
PC III	54	-0.152	1.792	0.244	89	0.092	1.593	0.169	(-0.198) [#]	0.72	0.3977
PC IV	54	-0.195	1.446	0.197	89	0.118	1.291	0.137	0.562	1.80	0.1815

¹Variable codes are principal component scores for axes I through IV.

[#]The r² is close to zero, and the adjustment caused the estimate to be negative, though this has no statistical interpretation (and should be set to zero).

significant sexual dimorphism (Table 1). Percentage-wise, mean size for males is only 1-2% larger than for females. The other crown dimension assessed here, crown height, comparably exhibits little sexual dimorphism. Just the mean size difference for U2 is significant statistically (a 4% difference), and crown heights of the mandibular incisors are virtually identical in the two sexes.

It seems noteworthy that overall tooth lengths of all four incisors are appreciably more dimorphic. All four ANOVA tests are significant (Table 1). Percent sexual dimorphism is lower but not trivial in the mandible (*ca.* 3%) and higher (*ca.* 5 to 8%) in the upper arch. This greater sexual dimorphism likewise is reflected in the coefficients of determination (r²) that can be read as the percentage of the variation in tooth length accounted for in the statistical sense by "sex." Percentages are lower for the two mandibular incisor types than in the maxilla, or, perhaps more correctly, the maxillary lateral incisor tooth length is comparatively highly dimorphic (r² = 14%).

It is evident that tooth length is composed of crown height and root length and, since sex differences in crown height are minor, most of the dimorphism obviously is due to sex differences in root length (Table 1). Indeed, sexual dimorphism in incisor root lengths is in the range of 5 to 8%, which is noticeably higher than for crown widths or heights. Also, unlike crown dimensions, percentage sex differences are not smaller for the mandibular root dimensions.

Crown-Root Ratios

Incisor crown-root ratios (Table 1) were here assessed for completeness. The ratio is simply crown height divided by root length, so the larger the ratio the more crown height contributes to overall tooth length. Ratios are 50% or less, showing that incisor root lengths characteristically are more than twice their crown heights. Mean crown-root ratios are slightly larger in the mandible because the mandibular root lengths are proportionately shorter. Sexual dimorphism for these ratios is trivial in the maxillary incisors, whereas both tests are significant for the mandibular incisor types.

These mandibular differences are due to longer roots in males (whereas the crown heights are very similar in men and women).

Correlation Matrix

Several studies have shown that tooth crown diameters are positively intercorrelated (reviewed, *e.g.*, in Henderson, 1975), and Garn *et al.* (1978a) showed that root lengths within individuals likewise covary in a positive fashion. These expectations are evident in the present data (Table 2) where all 120 pairwise correlations are positive and most are significantly different from zero statistically. Given the uniform sample size of 148 cases, correlations above 0.16 are significant ($P < 0.05$) and those above 0.21 are highly significant ($P < 0.01$).

Scanning the matrix, the weakest correlations are between crown widths and root lengths, and the strongest are between tooth lengths and root lengths. These latter are predictable, however, because root length is the major constituent of tooth length. Pearson and Davin (1924; also see Solow, 1966) term these sorts of correlations of a dimension plus part of itself "spurious" in the sense that they are correlated simply because of their geometric association, which need not be biological.

Ideally, one would like to find statistically independent axes of variation so that the sexual dimorphism exhibited by some tooth dimensions is not duplicative of that of other dimensions. Separate "axes" of variation would provide greater statistical power for discriminating between the sexes using multiple tooth dimensions. Given the consistently positive, generally high correlations here (Table 2) suggests that there is effectively just a single statistical (and, by inference, biological) axis of sexual dimorphism.

Principal Components Analysis

PCA (Gorsuch, 1983) was used to assess the relationships among the crown and root dimensions. Four dimensions for each of the four incisor tooth types were used in the analysis, namely (1) crown width, (2) tooth length, (3) crown height, and (4) root length. Four components were extracted with eigenvalues exceeding

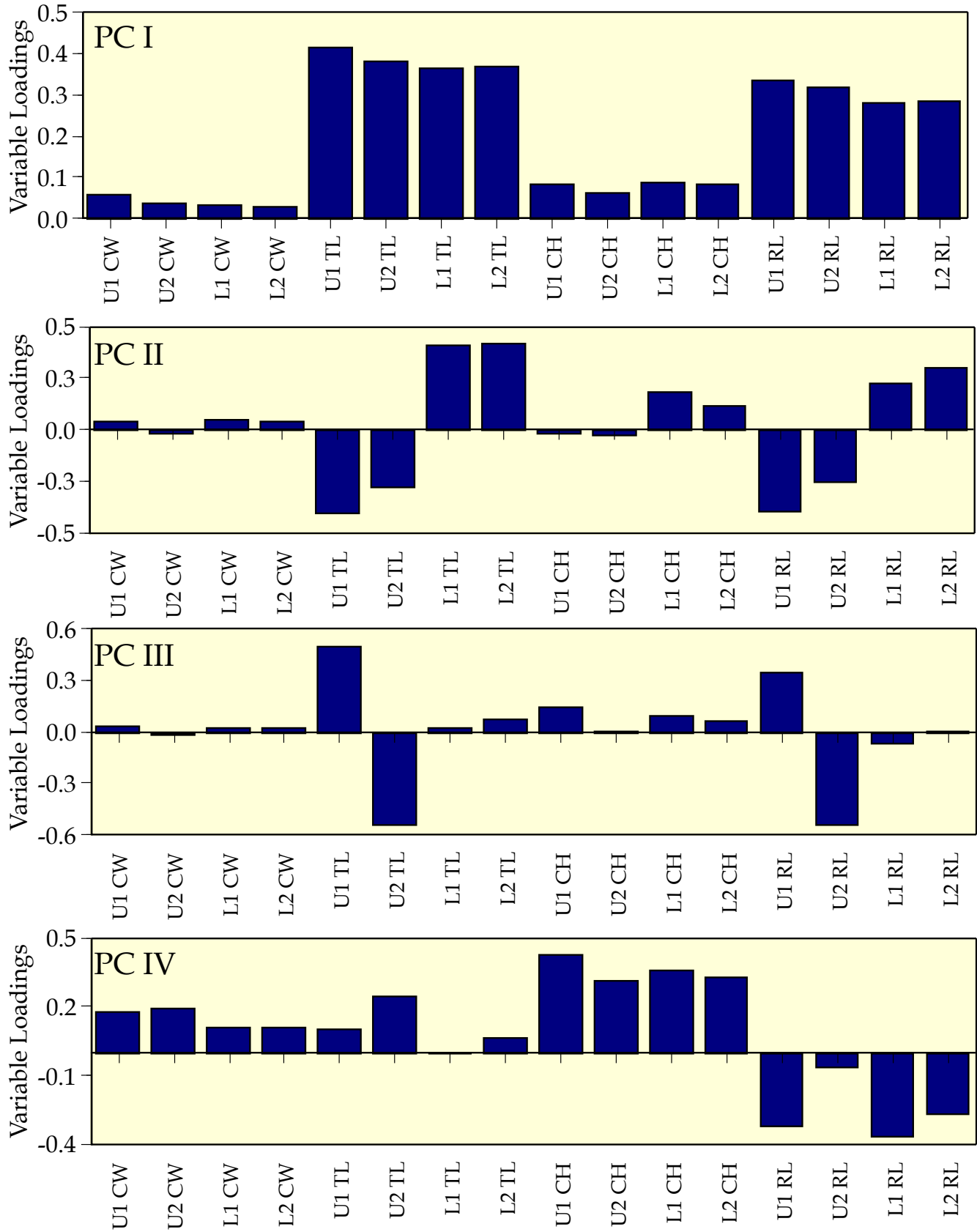


Fig. 2. Plots of the variable weights on the first four principal components extracted from the covariance matrix of 16 crown and root dimensions. These “weights” of variables with each canonical axis can be interpreted as the correlation coefficient of the variables with the axis.

one (Kaiser, 1970), and these were evaluated without matrix rotation (Table 3). These four axes account for most (91%) of the variation, and, within these, just the first axis is responsible for most (62%) of the total variance.

PC I is controlled by tooth length, with slightly higher weightings on the two maxillary dimensions (Fig. 2). Probably because root lengths are major constituents of tooth length (Fig. 1), root lengths also have comparatively high weightings on this component.

PC II reflects the high loadings of tooth lengths and root lengths, but here there are polarities (opposite signs) for variables in the maxilla and the mandible. As with the first component, crown widths and heights have only minor loadings (correlation coefficients) with PC II.

PC III is a further orthogonal axis of variation for root length and, by association, tooth length. Here just the maxillary variables exhibit high loadings, with polarities between the central and lateral incisors. In other words, having accounted for the variances of PC I and II, the

remaining major axis of variation is a contrast between root lengths of the two maxillary incisor types.

Highly weighted variables for PC IV are restricted to crown heights and root lengths (Fig. 2). Within a variable (crown height or root length), all four weights are of the same sign.

When tested for sexual dimorphism (Table 4), PC I scores, which depend primarily on root lengths, are highly significant. In contrast, none of the other three axes seems to be of any value for sex discrimination.

Discriminant Analysis

When the eight crown size variables (4 widths, 4 heights) were subjected to stepwise linear discriminant function analysis, just one variable—crown width of U1—was significantly predictive. Correct allocation was 47% overall, though somewhat higher in girls (56%) than boys (37%).

When the other eight variables were analyzed (4 tooth lengths, 4 root lengths), again there was just one significant predictor because of the considerable

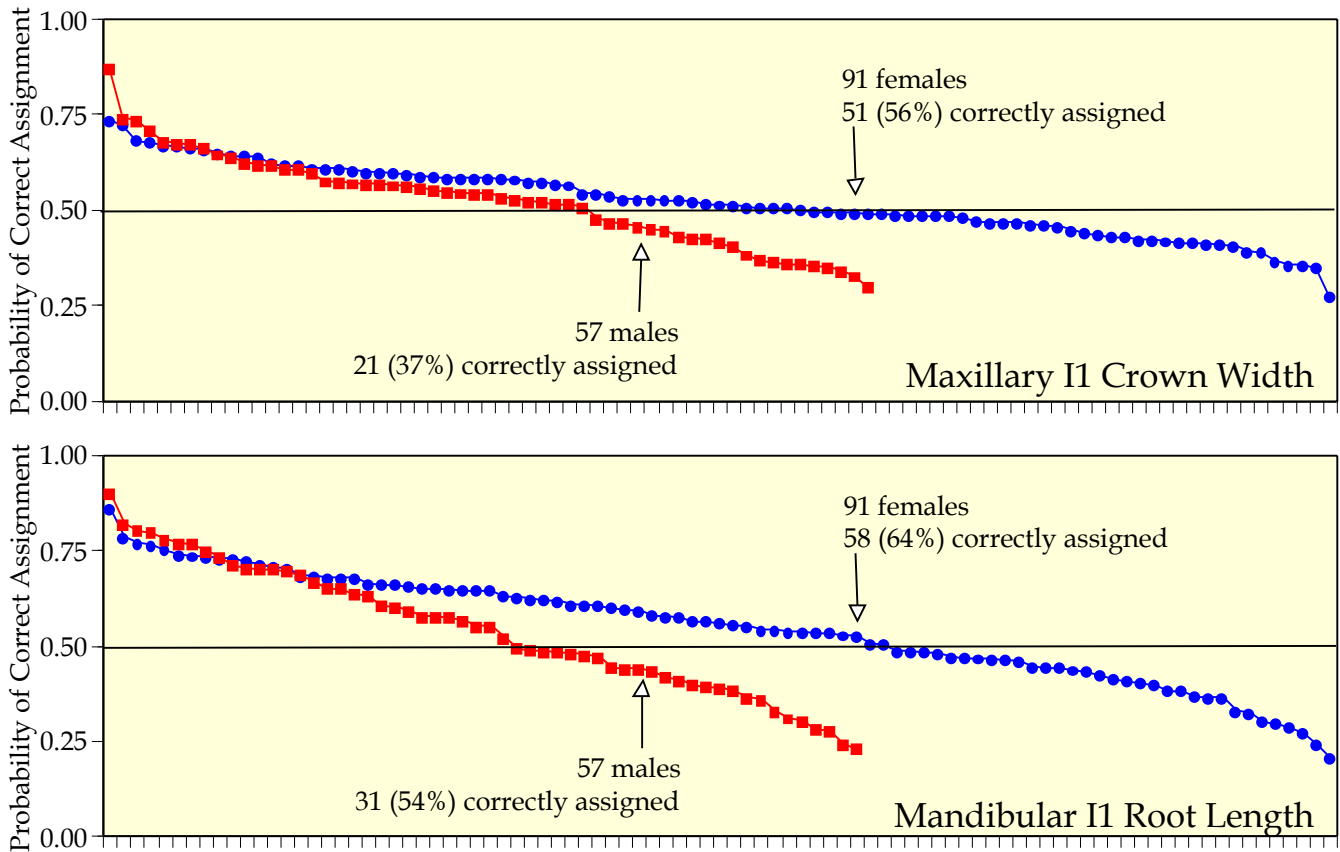


Fig. 3. Sequenced arrays of the probabilities of group assignment. Probabilities above 50% are the cases correctly assigned; cases with probabilities below 50% were allocated to the wrong sex. The height of the symbol above the 0.5 line is a measure of how confident the researcher can be that the case is correctly classified. The shallow slope of the distributions illustrates the weak sexual dimorphism even of these selected variables. *Top.* Arrays using U1 crown width, which is the one statistically significant crown size predictor of sex from among the 8 tested. *Bottom.* Arrays using mandibular I1 root length, which is the one significant root size predictor of sex in this sample from among the 8 tested.

statistical redundancy of these dimensions. Here, mandibular central incisor (L1) root length was most discriminating, with 60% correct assignment (54% for males; 64% for females). This is an improvement over using crown widths alone, but the increase in correct assignment (60% *vs.* 49%) is modest. One can see from the very gradual slope of probabilities of correct assignment (Fig. 3) that there is considerable overlap in crown and in root dimensions between the two sexes.

We supposed that there would be enough statistical independence between crown and root dimensions that they could be used in combination to improve sex determination. This was not the case. Once the greater dimorphism of root length was entered (specifically, inclusion of L1 root length at step 1) and statistics of the other variables were adjusted to account for root length, none of the other dimensions had significant independent power to be added. With hindsight, this is because all 16 of the variables studied here are positively intercorrelated, and even the weakest associations (between crown widths and root lengths) are still on the order of 0.1 to 0.2.

DISCUSSION

Tooth root size and morphology have been studied far less than crown size (*e.g.*, Kovacs, 1971; Thomas, 1995), largely because of their inaccessibility and, additionally, in archeological specimens, their comparative fragility. So too, little is known about the genetic control of root size and morphology. Most root formation occurs prior to tooth emergence (Carlson, 1944), which may be protective against forces of mastication until teeth are in function. Unlike enamel, a root's configuration is subject to surface remodeling. Root resorption can be instigated with orthodontic forces (Harris, 2000) or with jiggling forces that are common consequences of pathological loss of supporting crestal bone (Nyman *et al.*, 1978; Harris *et al.*, 1993).

The accretion of cementum, in contrast, increases root dimensions in an age-progressive manner (Wittwer-Backofen *et al.*, 2004), though the annual depositions are too small to be visualized on conventional radiographs. Cementum accumulation typically is thickest in the bifurcations of multirouted teeth, though hypercementosis occasionally occurs periapically (*e.g.*, Halstead and Hoard, 1991).

The normal age-progressive periapical accumulation of cementum needs to be studied in more detail; researchers have reported on an increase in root length—supposedly by cementum apposition—as an age-progressive event. Most such studies have been cross-sectional (Levers and Darling, 1983; Whittaker *et al.*, 1990), though there is some longitudinal evidence for root lengthening with age (Bishara *et al.*, 1999).

The prime focus in the present study was to test whether root lengths exhibit greater sexual dimorphism than crown dimensions, where sex differences are too

subtle to be definitive in most cases (Ditch and Rose, 1972; Kieser and Groeneveld, 1989). Precisely because sexual dimorphism is modest in humans, most studies that have developed discriminant functions capitalize on sex differences specific to their own sample; applications to other groups generally exhibit much weaker frequencies of correct sex assignment. The problem is intrinsic to the crown size data, not to sophistication of the statistical techniques. There are two synergistic problems, (1) there is little sexual dimorphism (the canines, especially buccolingually, seem to be the most dimorphic; Sciuilli *et al.*, 1977) and (2) even though teeth are numerous within a person, crown sizes all are significantly, positively intercorrelated, so there are few axes of novel information to exploit (*e.g.*, Moorrees and Reed, 1964; Potter *et al.*, 1968; Harris and Bailit, 1988); the sexual dimorphism seen among crown dimensions is statistically redundant.

These observations seem to have motivated Garn and coworkers (1979) and others to look for independent axes of variation. Tooth roots seem to offer two advantages here: (1) the dimensions are at least partially uncoupled from crown size (Fig. 2), so the data are not repetitive (statistically redundant) with crown dimensions, and (2) root lengths are a bit more dimorphic than crown dimensions (Table 1).

The present study has clear precedents in the work of Stanley Garn and colleagues (1978a,b, 1979) who measured root lengths in a sample of living American white teenagers using 45° oblique-jaw radiographs. They measured five mandibular tooth types (C, P1, P2, M1, M2) omitting the incisors that are distorted in this radiographic view. While their methodological details differ from ours, there are some key similarities. One, we examined different teeth than Garn's group, but our intertooth correlations (Table 2) for tooth lengths are in the same range, about 0.5 to 0.6, and the correlations within an arch are higher than between arches. Two, the correlations between crown size (here we tested mesiodistal incisor crown widths) and root lengths are low (*ca.* 0.1 to 0.2) but consistently positive. Garn *et al.* (1978b) found the same low level of crown-root integration.

Garn and coworkers (1979) tested the sex discriminatory power of numerous combinations of crown and root dimensions. Scrutiny of their presentation shows, however, that they made no effort to show that each variable in each discriminant function contributed significant statistically information. Alternatively, the simple addition of more variables typically will improve discrimination of individuals in the sample used to generate the formulae (discriminant functions) because using more variables capitalizes on variation unique to that sample. Unfortunately, amassing variables (1) does not improve the statistical significance of the predictive equation and (2) detracts from the generalizability of the results to other samples (Kieser and Groeneveld, 1989).

In other words, "percentage correct allocation" should not be the driving criterion for developing discriminant functions because that criterion commonly is specific to the sample used to develop the functions—that criterion promotes exploiting male-female differences specific to that sample, not to sex differences in size relationships at large.

Tooth roots serve several functions (Shafer *et al.*, 1983), including the important function of transmitting the forces of occlusion to the supporting alveolar bone. Given the significantly larger bite forces in males than females, especially after the onset of puberty (*e.g.*, Bakke *et al.*, 1990; Julien *et al.*, 1996), the tendency for larger roots (with larger surface areas) in men probably is adaptive. As Garn noted (1978b, p 636):

It is impressive that the crowns of permanent teeth that begin to form by the second trimester of prenatal life and that complete their size-attainment in the second to fifth year of postnatal life thus "anticipate" the length of still-to-be-completed roots by 10 years or more.

CONCLUSIONS

This study of incisor crown-root dimensions in a contemporary American white sample shows that root lengths are somewhat more sexually dimorphic than crown dimensions and, thus, are somewhat more useful for sex determination. The statistical associations are higher among crown dimensions than between crowns and roots, but all correlations are positive. Our discriminant function analysis (that relied just on incisor tooth types) does not support the supposition that combinations of crown and root dimensions are any more useful for sex determination than root dimensions alone—because the dimensions all seem to reflect the same statistical information. Perhaps the use of more tooth types, notably the canine, would somewhat improve correct sex assignment from tooth dimensions.

LITERATURE CITED

- Bakke M, Holm B, Jensen BL, Michler L, Moller E. 1990. Unilateral, isometric bite force in 8-68-year-old women and men related to occlusal factors. *Scand J Dent Res* 98:149-158.
- Bishara SE, Vonwald L, Jakobsen JR. 1999. Changes in root length from early to mid-adulthood: resorption or apposition? *Am J Orthod Dentofacial Orthop* 115:563-568.
- Brezniak N, Wasserstein A. 1993a. Root resorption after orthodontic treatment: Part 1. literature review. *Am J Orthod Dentofacial Orthop* 103:62-75.
- Brezniak N, Wasserstein A. 1993b. Root resorption after orthodontic treatment: Part 2. literature review. *Am J Orthod Dentofacial Orthop* 103:138-146.
- Carlson H. 1944. Studies on the rate and amount of eruption of certain human teeth. *Am J Orthod Oral Surg* 30:575-588.
- Cooley WW, Lohnes PR. 1971. *Multivariate data analysis*. New York: John Wiley & Sons, Inc.
- De Vito C, Saunders SR. 1990. A discriminant function analysis of deciduous teeth to determine sex. *J Forensic Sci* 35:845-858.
- Ditch LE, Rose JC. 1972. A multivariate dental sexing technique. *Am J Phys Anthropol* 37:61-64.
- Garn SM, Cole PE, Van Alstine WL. 1979. Sex discriminatory effectiveness using combinations of root lengths and crown diameters. *Am J Phys Anthropol* 50:115-118.
- Garn SM, Lewis AB, Swindler DR, Kerewsky RS. 1967. Genetic control of sexual dimorphism in tooth size. *J Dent Res* 46:963-972.
- Garn SM, Van Alstine WL Jr, Cole PE. 1978a. Intraindividual root-length correlations. *J Dent Res* 57:270.
- Garn SM, Van Alstine WL Jr, Cole PE. 1978b. Relationship between root lengths and crown diameters of corresponding teeth. *J Dent Res* 57:636.
- Gorsuch R. 1983. *Factor analysis*, 2nd ed. Hillsdale: Lawrence Erlbaum Publishers.
- Halstead CL, Hoard BC. 1991. Dental radiology and oral pathology. *Curr Probl Diagn Radiol* 20:187-235.
- Harris EF. 2000. External apical root resorption resulting from orthodontic tooth movement. *Semin Orthod* 6:183-194.
- Harris EF, Bailit HL. 1988. A principal components analysis of human odontometrics. *Am J Phys Anthropol* 75:87-99.
- Harris EF, McKee JH. 1990. Tooth mineralization standards for blacks and whites from the middle southern United States. *J Forensic Sci* 35:859-872.
- Harris EF, Robinson QC, Woods MA. 1993. An analysis of causes of apical root resorption in patients not treated orthodontically. *Quintessence Int* 24:417-428.
- Henderson AM. 1975. *Dental Field Theory: An Application to Primate Dental Evolution*. Ph.D. dissertation, University of Colorado, Boulder.
- Julien KC, Buschang PH, Throckmorton GS, Dechow PC. 1996. Normal masticatory performance in young adults and children. *Arch Oral Biol* 41:69-75.
- Kaiser HF. 1970. A second generation Little Jiffy. *Psychometrika* 35:401-415.
- Kieser JA, Groeneveld HT. 1989. Allocation and discrimination based on human odontometric data. *Am J Phys Anthropol* 79:331-338.
- Koppe T, Swindler DR. 2004. Metric sexual dimorphism in the deciduous teeth of Old World monkeys. *Ann Anat* 186:367-374.
- Kovacs I. A systematic description of dental roots. In: Dahlberg AA, ed. *Dental morphology and evolution*. Chicago: University of Chicago Press.
- Krogman WM, Iscan MY. 1986. *The human skeleton in forensic medicine*, 2nd ed. Springfield: Charles C. Thomas Publisher.

- Levers BGH, Darling AI. 1983. Continuous eruption of some adult human teeth of ancient populations. *Arch Oral Biol* 28:401-408.
- Manning JT. 2002. Digit ratio: a pointer to fertility, behaviour, and health. New Brunswick, NJ: Rutgers University Press.
- Moorrees CFA, Reed RB. 1964. Correlations among crown diameters of human teeth. *Arch Oral Biol* 9:685-697.
- Nyman S, Lindhe J, Ericsson I. 1978. The effect of progressive tooth mobility on destructive periodontitis in the dog. *J Clin Periodontol* 5:213-225.
- Owsley DW, Webb RS. 1983. Misclassification probability of dental discrimination functions for sex determination. *J Forensic Sci* 28:181-185.
- Pearson K, Davin A. 1924. On the biometric constants of the human skull. *Phil Mag, series 6*, 2:559-572.
- Potter RH, Yu P-L, Dahlberg AA, Merritt AD, Conneally PM. 1968. Genetic structure of tooth size factors in size factors in Pima Indian families. *Am J Hum Genet* 20:89-100.
- Rhee SH, Nahm DS. 2000. Triangular-shaped incisor crowns and crowding. *Am J Orthod Dentofacial Orthop* 118:624-628.
- Rohlf FJ, Sokal RR. 1981. *Statistical tables*, 2nd ed. San Francisco: WH Freeman and Company.
- Sciulli PW, Williams JA, Gugelchuk GM. 1977. Canine size: an aid in sexing prehistoric Amerindians. *J Dent Res* 56:1424.
- Shafer WG, Hine MK, Levy BM. 1983. *A textbook of oral pathology*, 4th ed. Philadelphia: WB Saunders Company.
- Solow B. 1966. The pattern of craniofacial associations: A morphological and methodological correlation and factor analysis study of young adult males. *Acta Odont Scand, suppl* 46:1-174.
- Swindler DR. 2002. *Primate dentition: an introduction to the teeth of non-human primates*. Cambridge: Cambridge University Press.
- Tanner JM, Prader A, Habich H, Ferguson-Smith MA. 1959. Genes on the Y chromosome influencing rate of maturation in man: skeletal age studies in children with Klinefelter's (XXY) and Turner's (XO) syndromes. *Lancet* 2:141-144.
- Teschler-Nicola M, Prossinger H. 1998. Sex determination using tooth dimensions. In: Alt KW, Rösing FW, Teschler-Nicola M, editors. *Dental anthropology: fundamentals, limits, and prospects*. Wien: Springer, p 479-500.
- Thomas HF. 1995. Root formation. *Int J Dev Biol* 3:231-237.
- Ubelaker DH. 1999. *Human skeletal remains*, 3rd ed. Washington: Taraxacum.
- Whittaker DK, Griffiths S, Robson A, Roger-Davies P, Thomas G, Molleson T. 1990. Continuing tooth eruption and alveolar crest height in an eighteenth-century population from Spitalfields, east London. *Arch Oral Biol* 35:81-85.
- Winer BJ, Brown DR, Michels KM. 1991. *Statistical principles in experimental design*, 3rd ed. New York: McGraw-Hill Book Company.
- Wittwer-Backofen U, Gampe J, Vaupel JW. 2004. Tooth cementum annulation for age estimation: results from a large known-age validation study. *Am J Phys Anthropol* 123:119-129.
- Zeisz RC, Nuckolls J. 1949. *Dental anatomy*. St Louis: CV Mosby Company.

14th International Symposium on Dental Morphology

Greifswald, Germany, August 20 – 23, 2008

We are very pleased to invite researchers from around the world to present and discuss cutting edge work on the many aspects of dental morphology of primates and other vertebrates. Like the former meetings, the program will be structured to encourage scientific discussions while interweaving social events that reflect the cultural heritage of this fascinating area of Northern Germany.

Organizers

Dr. Thomas Koppe, Greifswald, Germany
 Prof. Dr. Kurt W. Alt, Mainz, Germany
 Prof. Dr. Georg Meyer, Greifswald, Germany

Scientific Program

The conference will include keynote lectures, plenary lectures, single and poster sessions, including sessions on:

- Dental evolution
- Dental anthropology
- Dental genetics
- Dental ontogeny
- Morphological integration within Dental and craniofacial complex
- Technology
- Miscellaneous



View of Greifswald University

For more information please contact

Dr. Th. Koppe
 Department of Anatomy and Cell
 Biology
 Ernst Moritz Arndt University
 Friedrich Loefflerstrasse 23c
 D-17489 Greifswald (Germany)

Telephone: +49 3834 865318
 Facsimile: +49 3834 865302
 Email: thokoppe@uni-greifswald.de
 altkw@mail.uni-mainz.de
 gemeyer@uni-greifswald.de
 or

<http://www.medizin.uni-greifswald.de/anatomie/>



View of Wieck, near Greifswald

NOTICE TO CONTRIBUTORS

Dental Anthropology publishes research articles, book reviews, announcements and notes and comments relevant to the membership of the *Dental Anthropology Association*. Editorials, opinion articles, and research questions are invited for the purpose of stimulating discussion and the transfer of information. Address correspondence to the Editor, Dr. Edward F. Harris, Department of Orthodontics, University of Tennessee, Memphis, TN 38163 USA (E-mail: eharris@utmem.edu).

Research Articles. The manuscript should be in a uniform style (one font style, with the same 10- to 12-point font size throughout) and should consist of seven sections in this order:

Title page	Tables
Abstract	Figure Legends
Text	Figures
Literature Cited	

The manuscript should be double-spaced on one side of 8.5 x 11" paper (or the approximate local equivalent) with adequate margins. All pages should be numbered consecutively, beginning with the title page. Submit three (3) copies – the original and two copies – to the Editor at the address above. Be certain to include the full address of the corresponding author, including an E-mail address. All research articles are peer reviewed; the author may be asked to revise the paper to the satisfaction of the reviewers and the Editor. All communications appear in English.

Title Page. This page contains (a) title of the paper, (b) authors' names as they are to appear in publication, (c) full institutional affiliation of each author, (d) number of manuscript pages (including text, references, tables, and figures), and (3) an abbreviated title for the header. Be certain to include a working E-mail address and/or telephone number.

Abstract. The abstract does not contain subheadings, but should include succinct comments relating to these five areas: introduction, materials, methods, principal results, and conclusion. The abstract should not exceed 200 words. Use full sentences. The abstract has to stand alone without reference to the paper; avoid citations to the literature in the abstract.

Figures. One set of the original figures must be provided with the manuscript in publication-ready format. Drawings and graphics should be of high quality in black-and-white with strong contrast. Graphics on heavy-bodied paper or mounted on cardboard are encouraged; label each on the back with the author's name, figure number, and orientation. Generally it is preferable to also send graphs and figures as computer files that can be printed at high resolution (600 dpi or higher). Most common file formats (Windows or Macintosh) are acceptable; check with the Editor if there is a question. The journal does not support color illustrations. Print each table on a separate page. Each table consists of (a) a table legend (at top) explaining as briefly as possible the contents of the table, (b) the table proper, and (c) any footnotes (at the bottom) needed to clarify contents of the table. Whenever possible, provide the disk-version of each table as a tab-delimited document; do not use the "make table" feature available with most word-processing programs. Use as few horizontal lines as possible and do *not* use vertical lines in a table.

Literature Cited. *Dental Anthropology* adheres strictly to the current citation format of the *American Journal of Physical Anthropology*. Refer to a current issue of the *AJPA* or to that association's web-site since the "current" style is periodically updated. As of this writing, the most recent guidelines have been published in the January, 2002, issue of the *AJPA* (2002;117:97-101). *Dental Anthropology* adheres to the in-text citation style used by the *AJPA* consisting of the author's last name followed by the year of publication. References are enclosed in parentheses, separated by a semicolon, and there is a comma before the date. Examples are (Black, 2000; Black and White, 2001; White *et al.*, 2002). The list of authors is truncated and the Latin abbreviation "*et al.*" is substituted when there are three or more authors (Brown *et al.*, 2000). However, *all* authors of a reference are listed in the Literature Cited section at the end of the manuscript.

Electronic Submission. Electronic submission *in addition to* sending hard copies of articles is strongly encouraged. For articles that undergo peer review, the editor will request submission of the final revision of a manuscript in electronic format, not interim versions. Files can be submitted on a 3.5" diskette, or a 100-megabyte Iomega Zip disk or a compact disk (CD), either in Windows or Macintosh format. **Files can also be sent as E-mail attachments.** Microsoft Word documents are preferred, but most common formats are suitable. Submit text and each table and figure as a separate file. Illustrations should be sent in PDF or EPS format, or check with the Editor before submitting other file types. Be certain to label any disk with your name, file format, and file names.

Dental Anthropology

Volume 19, Number 3, 2006

Original Articles

- Carolina Rodríguez and Freddy Moreno
Paramolar tubercle in the left maxillary second premolar: a case report 65
- Abdulla Al-Shorman
**A Byzantine Cranium from Jordan: A Case Study
in Dental Anthropology 79**
- Edward F. Harris and W. Max Couch
**The Relative Sexual Dimorphism of Human
Incisor Crown and Root Dimensions. 87**

Brief Communication

- Vincent H. Stefan
**Rotation of the Maxillary Premolars: Evidence
in Support of Premolar Morphogenetic Field 70**
- Commentary* by Edward F. Harris 74
- Carlos David Rodríguez Florez, Gabriel Mario Fonseca,
and Maria Teresa de Villalba
**Occurrence of an Eighth Cusp on Primary Second
Mandibular Molars of a Contemporary Argentinean Child 83**

DAA News

- The Albert A. Dahlberg Competition, 2007 86**
- 14th International Symposium on Dental Morphology
Greifswald, Germany, August 20 - 23, 2008 96**

Published at
Craniofacial Biology Laboratory, Department of Orthodontics
College of Dentistry, The Health Science Center
University of Tennessee, Memphis, TN 38163 U.S.A.

The University of Tennessee is an EEO/AA/Title IX/Section 504/ADA employer